

Complex Catheter Therapeutics 2004

Case Presentations

Co-medical Live

Oct. 22(Fri), 2004 Kobe



CCT 2004

CCT 2004 Live Case Demonstrations

Toyohashi Heart Center

Case 2-27 S. K. 82 歳 女性

Target Lesion: 右冠動脈 (#4PL)
左前下行枝 (#7)

診断名: OMI, AP

冠インターベンションの既往:

'90.2.5 POBA(LAD AMI)

'97.10.3 Stent (RCA gfx)

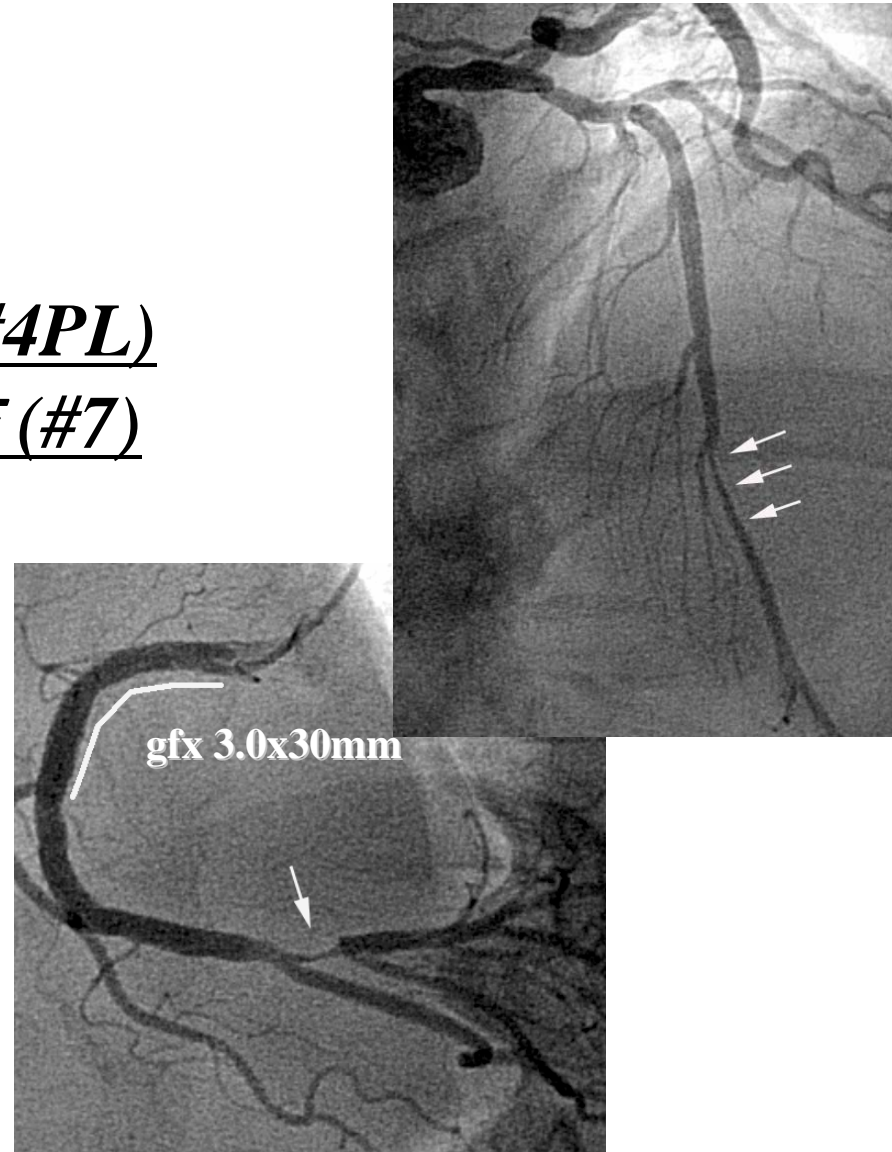
冠危険因子:

高血圧症

最終診断カテ: '04.10.4

LVG: Seg. 2,3,6 akinesis, LVEF: 41%

CAG: *distal RCA 90%, distal LAD 90%*





CCT 2004 Live Case Demonstrations

Toyohashi Heart Center

CCT 2004

Case 2-20 T. N. 71 y.o. male

Target Lesion: LAD??

Diagnosis: OMI

Present illness:

- '94.10.12 Guide wire unpass (*RCA-CTO*)
- '00.10.6 Guide wire unpass (*RCA-CTO*)
- '04.10.13 *LAD* stenosis suspected by MSCT

Coronary risk factor:

Smoking

Final CAG findings: '00.2.9

LVEF: 47%

CAG: *Prox. RCA* 100%,

