

CCT 2004

CCT 2004 Ablation Live Case Demonstrations

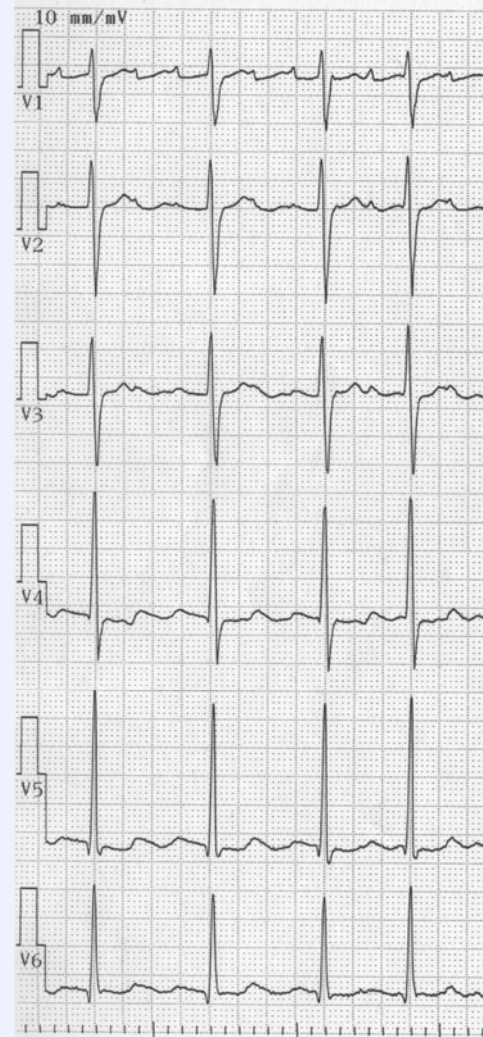
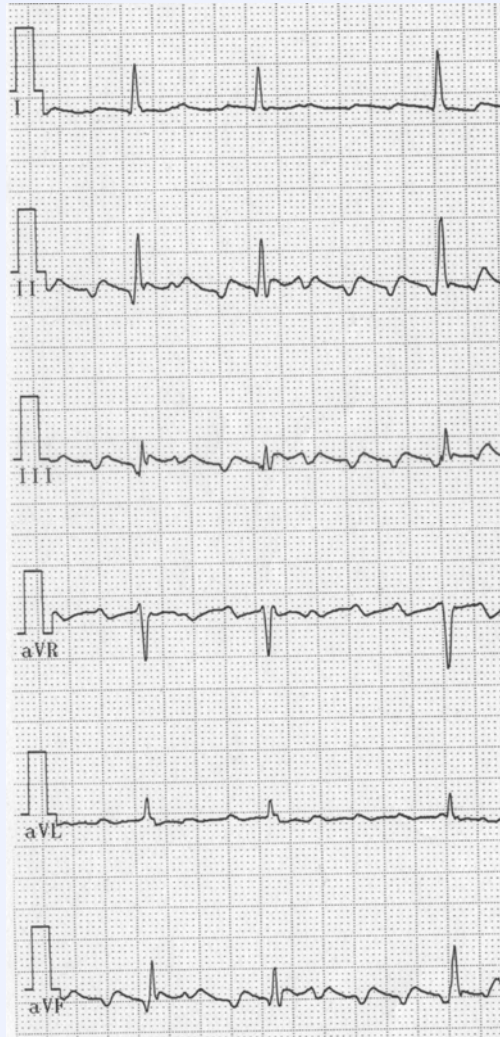
Shiga Prefectural Medical Center for Adult Disease


Case 3-1 71 y.o. male

Diagnosis; common type Atrial Flutter

Present Illness; tachyarrhythmia since Aug 2004, Hypertension

ECG





CCT 2004

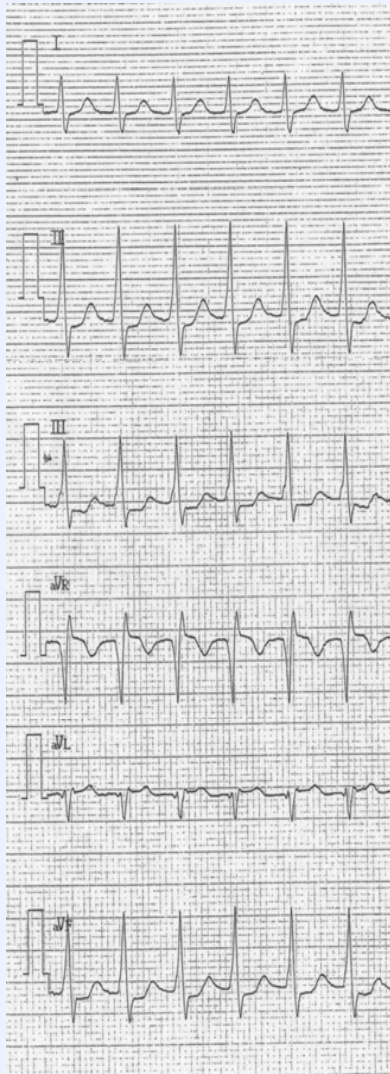
CCT 2004 Ablation Live Case Demonstrations

Shiga Prefectural Medical Center for Adult Disease

Case 3-2 63 y.o. male

Present Illness; paroxysmal tachycardia since 15 years ago, terminated by Valsalva maneuver

PSVT



SR

