


## CCT 2004 Ablation Live Case Demonstrations

### *Yokohama Red Cross Hospital*

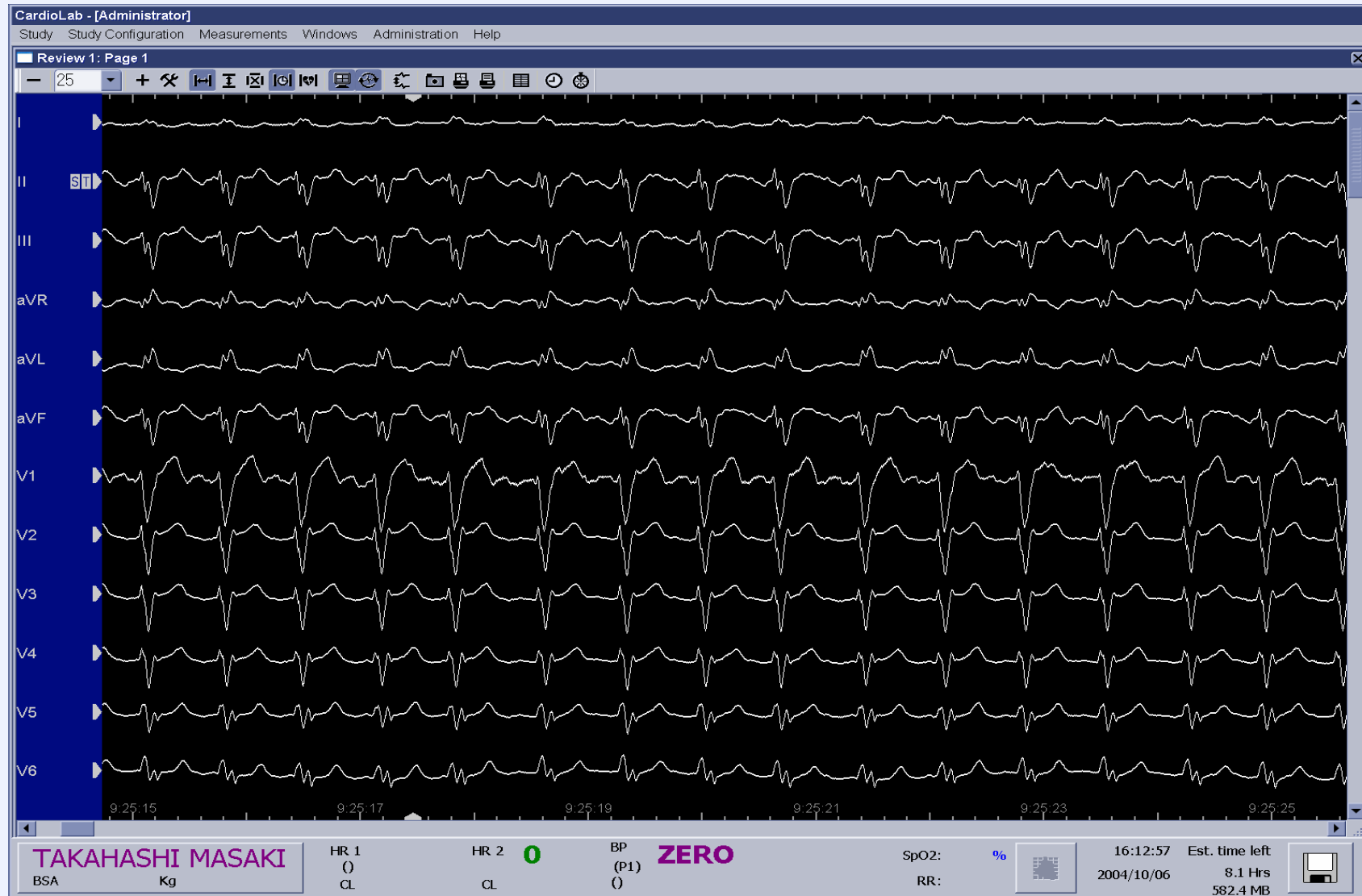
#### ***Case 1-1***


- Name: M.T. 79 yrs Male
- P.H.: CHF
- S/P Hepatic cancer
- B.P.;98/52 HR;78bpm
- HPI: He was transferred from the remote hospital for the RF catheter ablation for his refractory atrial flutter of common variety.



# CCT 2004 Ablation Live Case Demonstrations

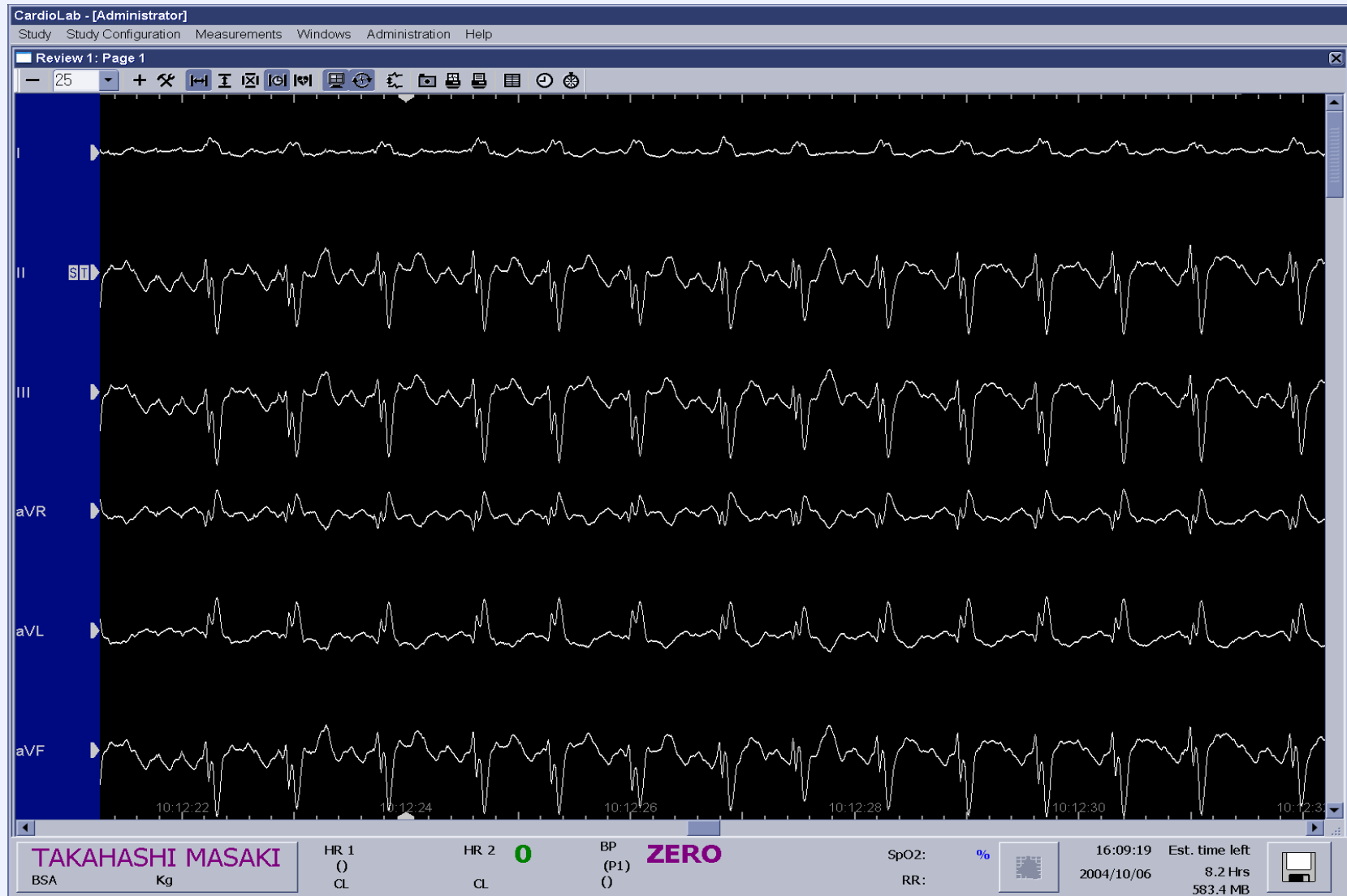## Yokohama Red Cross Hospital






# CCT 2004 Ablation Live Case Demonstrations

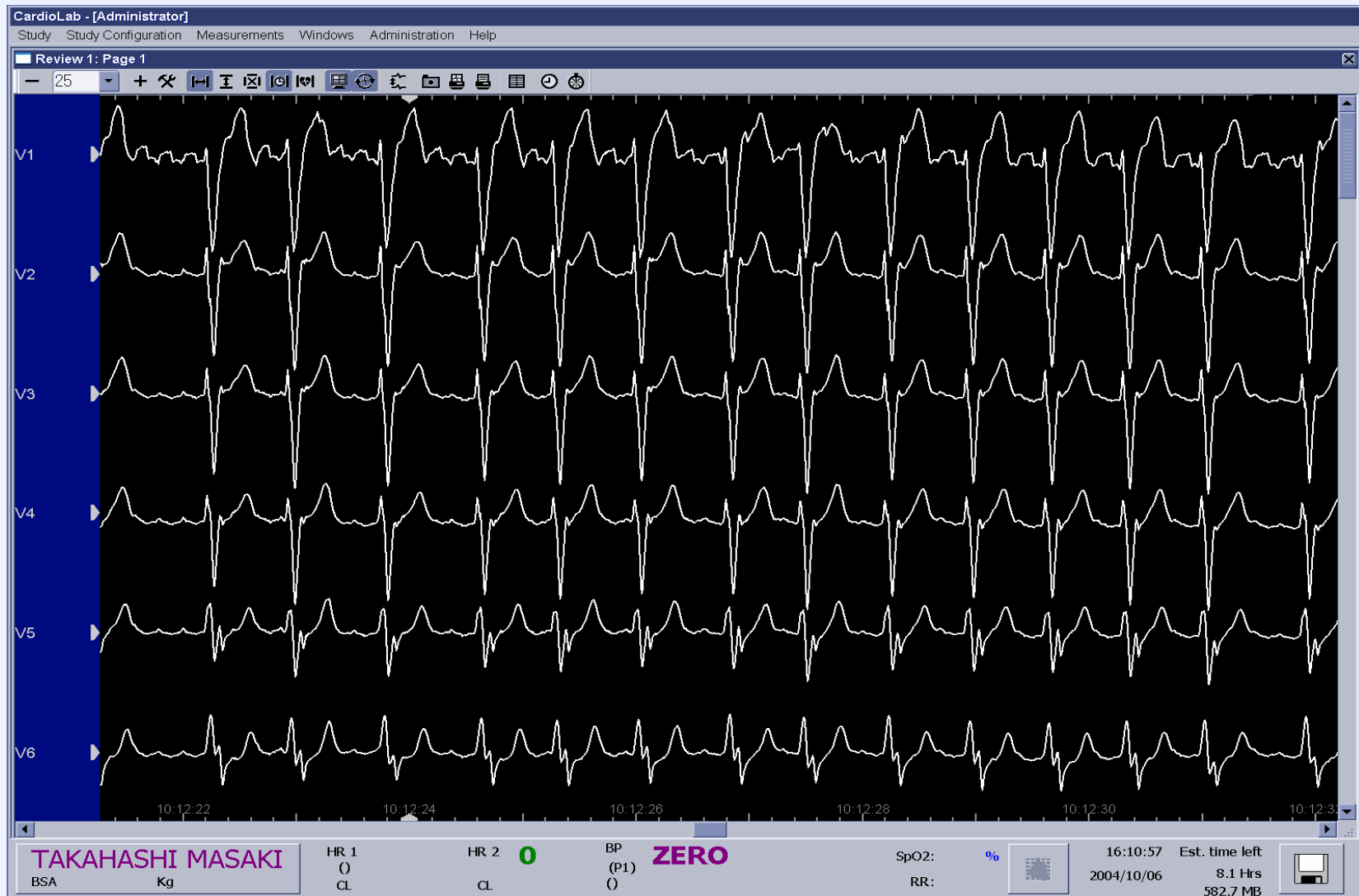
## Yokohama Red Cross Hospital






# CCT 2004 Ablation Live Case Demonstrations

## Yokohama Red Cross Hospital






## CCT 2004 Ablation Live Case Demonstrations

### *Yokohama Red Cross Hospital*

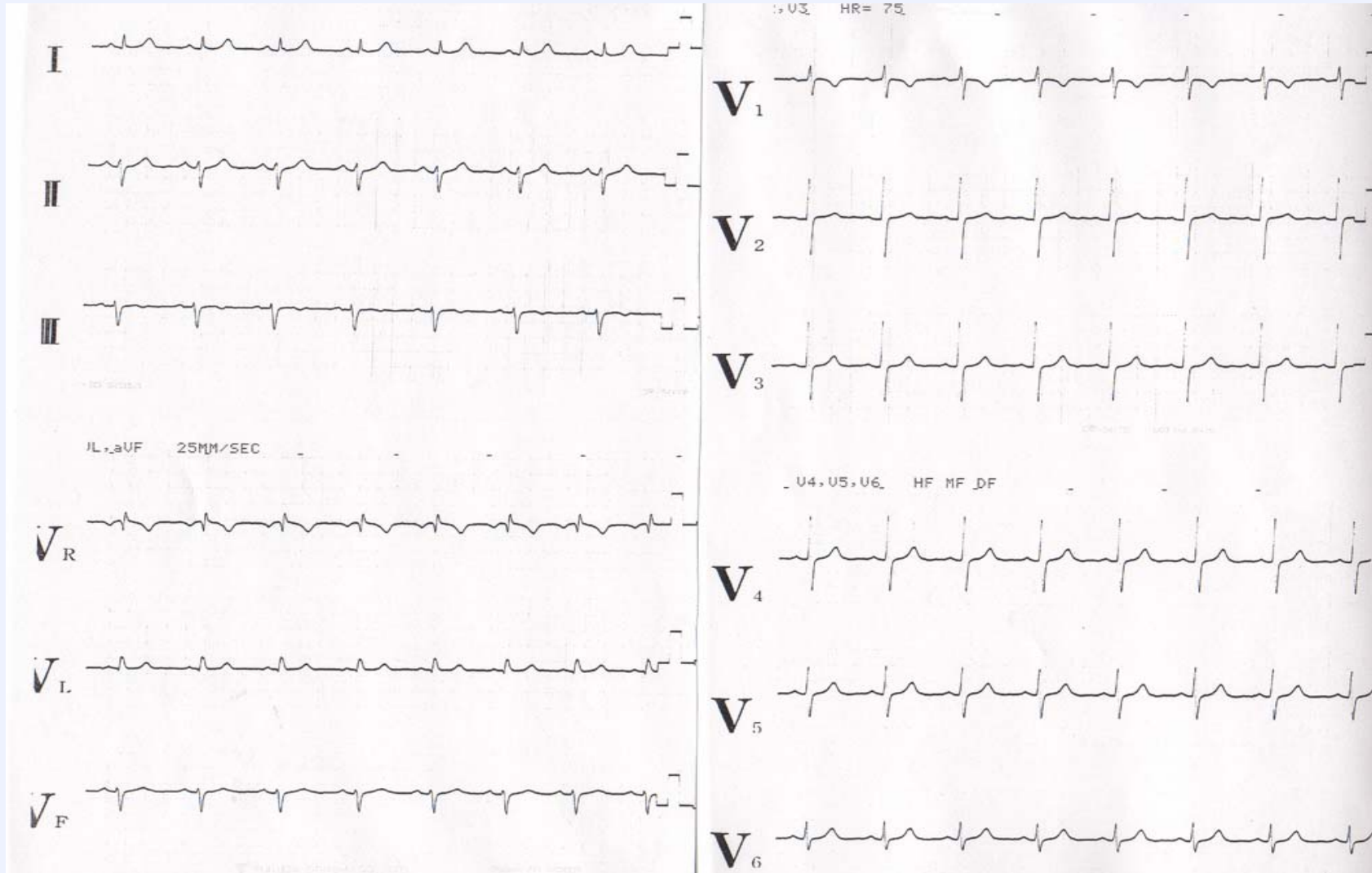
#### *Case 1-2*

- 症例： N. S. 60歳 女性
- 現病歴：昭和63年頃より動悸発作起こす。
  - verapamilにてコントロールしていたが、最近薬剤抵抗性となったため近医より紹介。
- これまでdisopyramide, procainamide,  $\beta$ -blockade使用するも十分な効果得られず。
- 患者本人もアブレーション希望のため来院。




# CCT 2004 Ablation Live Case Demonstrations

## Yokohama Red Cross Hospital

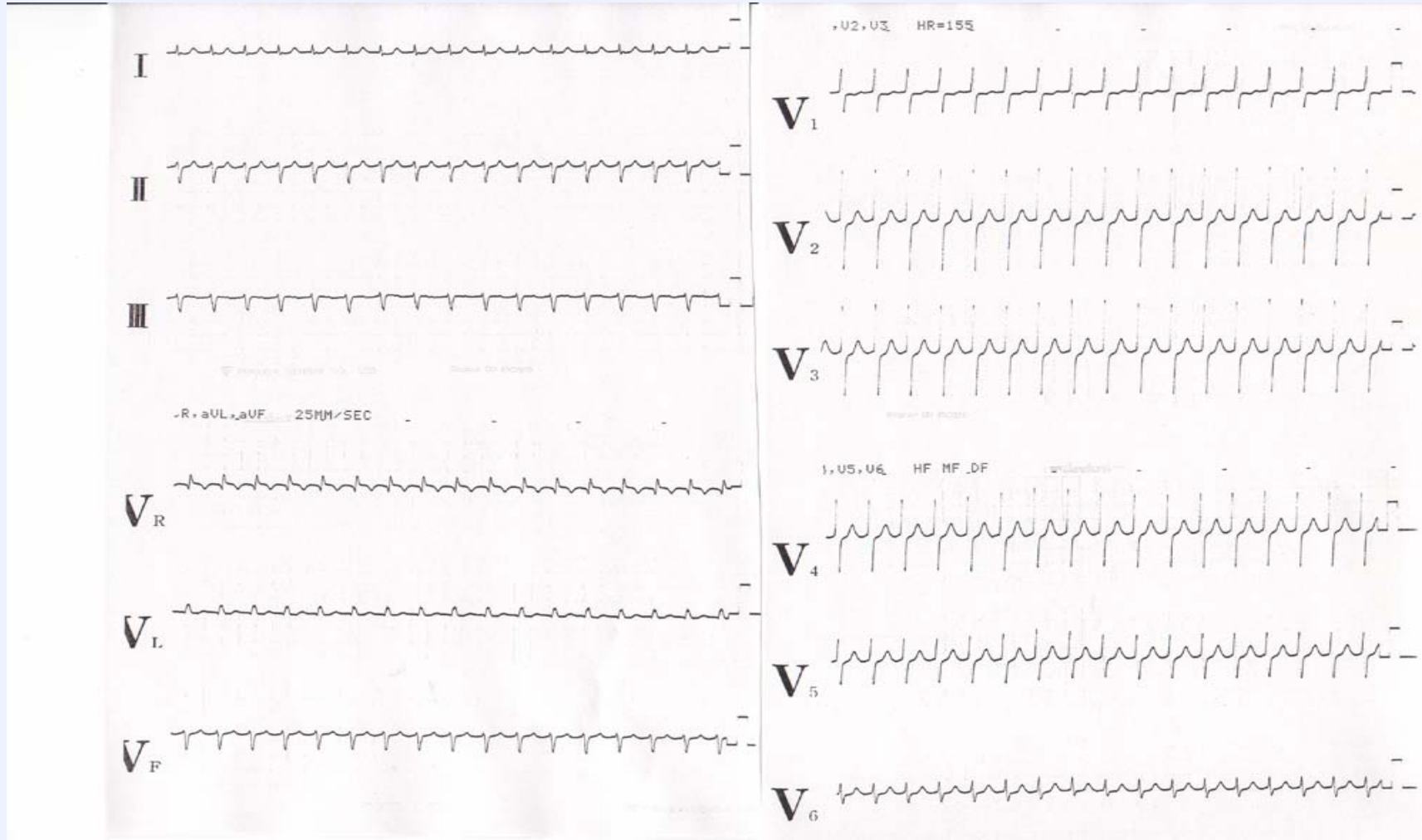


CASE 3 12ECG-NSR




# CCT 2004 Ablation Live Case Demonstrations

## Yokohama Red Cross Hospital



CASE 2 PSVT 12ECG




## CCT 2004 Ablation Live Case Demonstrations

### *Yokohama Red Cross Hospital*

#### *Case 1-3*

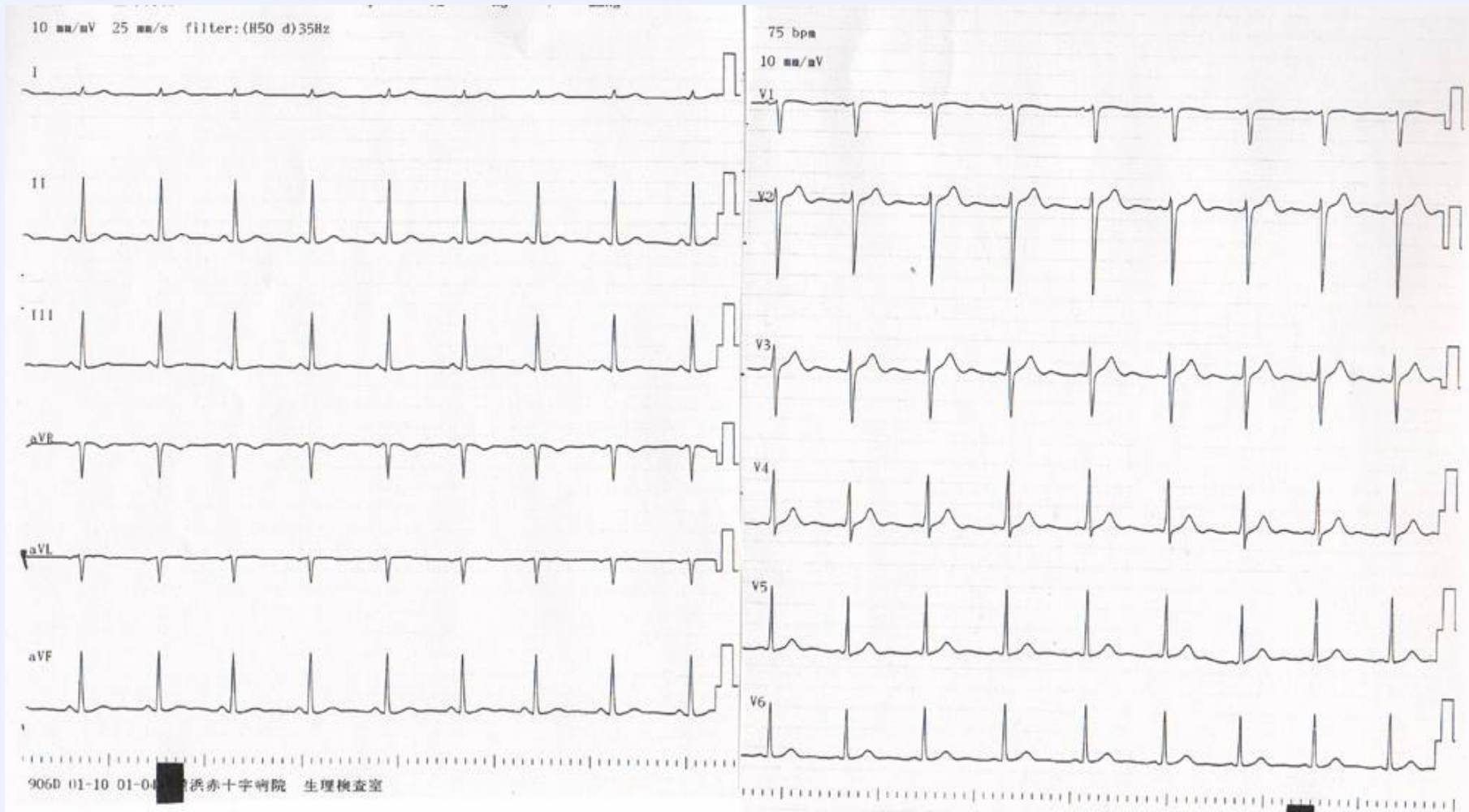
- 症例:F. O. 40歳女性
- 現病歴:数年前より動悸発作あり近医受診しPSVTが診断された。VerapamilにてNSRに復帰。
- カテーテルアブレーション目的にて紹介。






# CCT 2004 Ablation Live Case Demonstrations

## Yokohama Red Cross Hospital

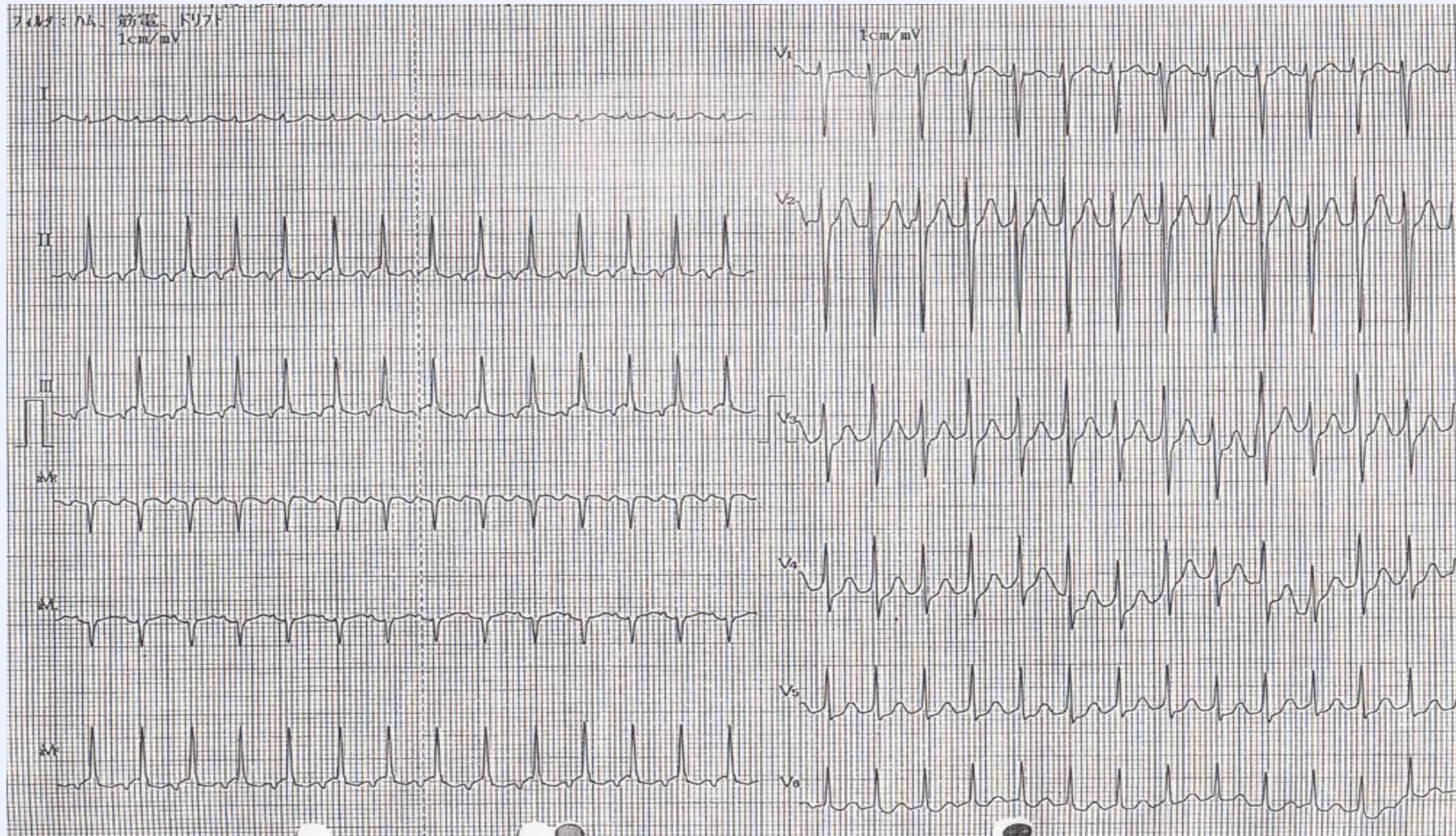


CASE 3 12ECG-NSR




# CCT 2004 Ablation Live Case Demonstrations

## Yokohama Red Cross Hospital



CASE 3 12ECG-PSVT




## CCT 2004 Ablation Live Case Demonstrations

*Yokohama Red Cross Hospital*

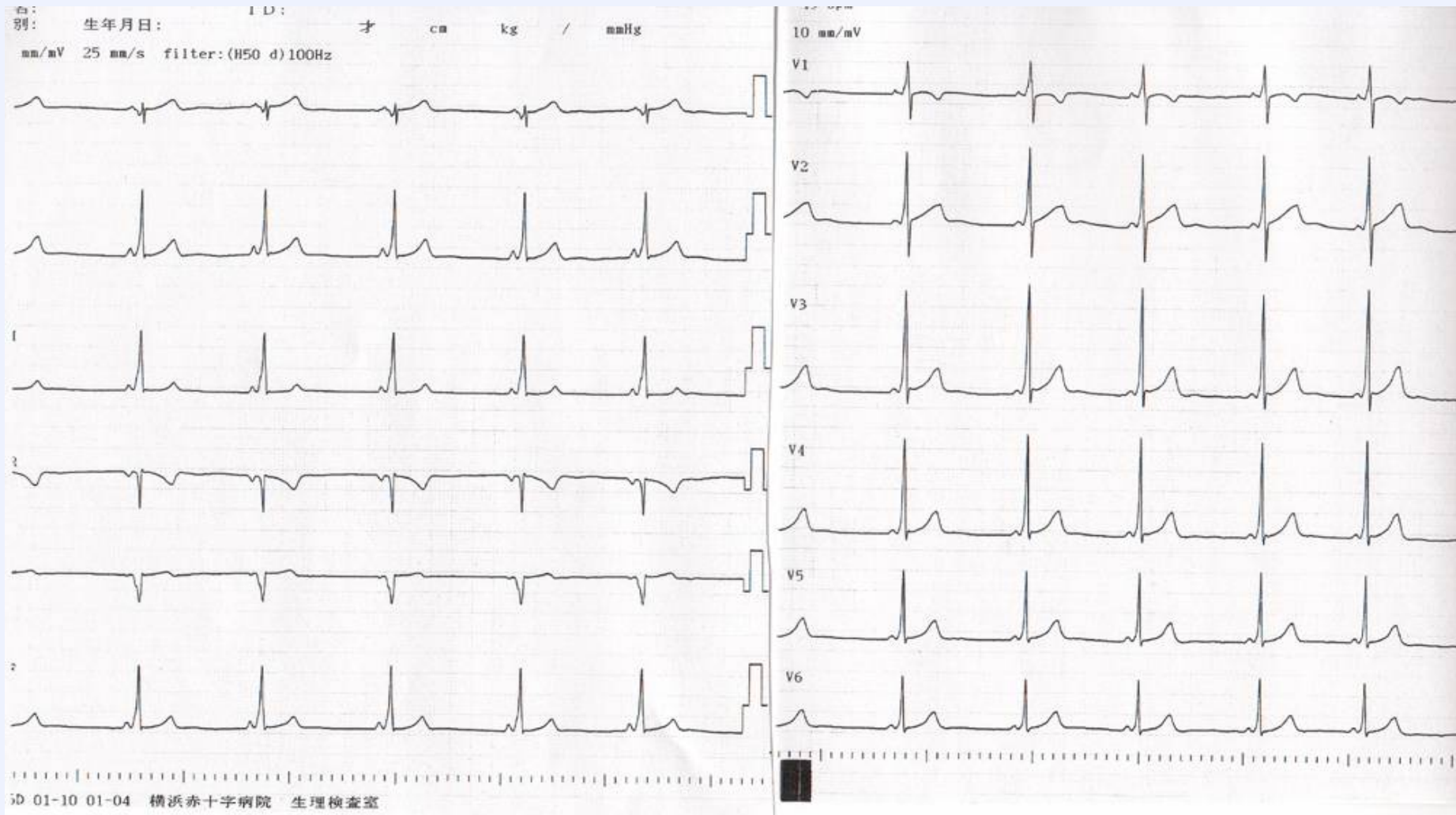### *Case 1-4*

- 症例：S. S. 24歳 女性
- 現病歴：学童期にWPW指摘されるも頻拍発作なきため放置されていた。
- 数年前から動悸発作起こるようになり、また最近発作回数増えたため当科受診。
-




# CCT 2004 Ablation Live Case Demonstrations

## Yokohama Red Cross Hospital



CASE 4 12ECG-NSR




## CCT 2004 Ablation Live Case Demonstrations

*Yokohama Red Cross Hospital*

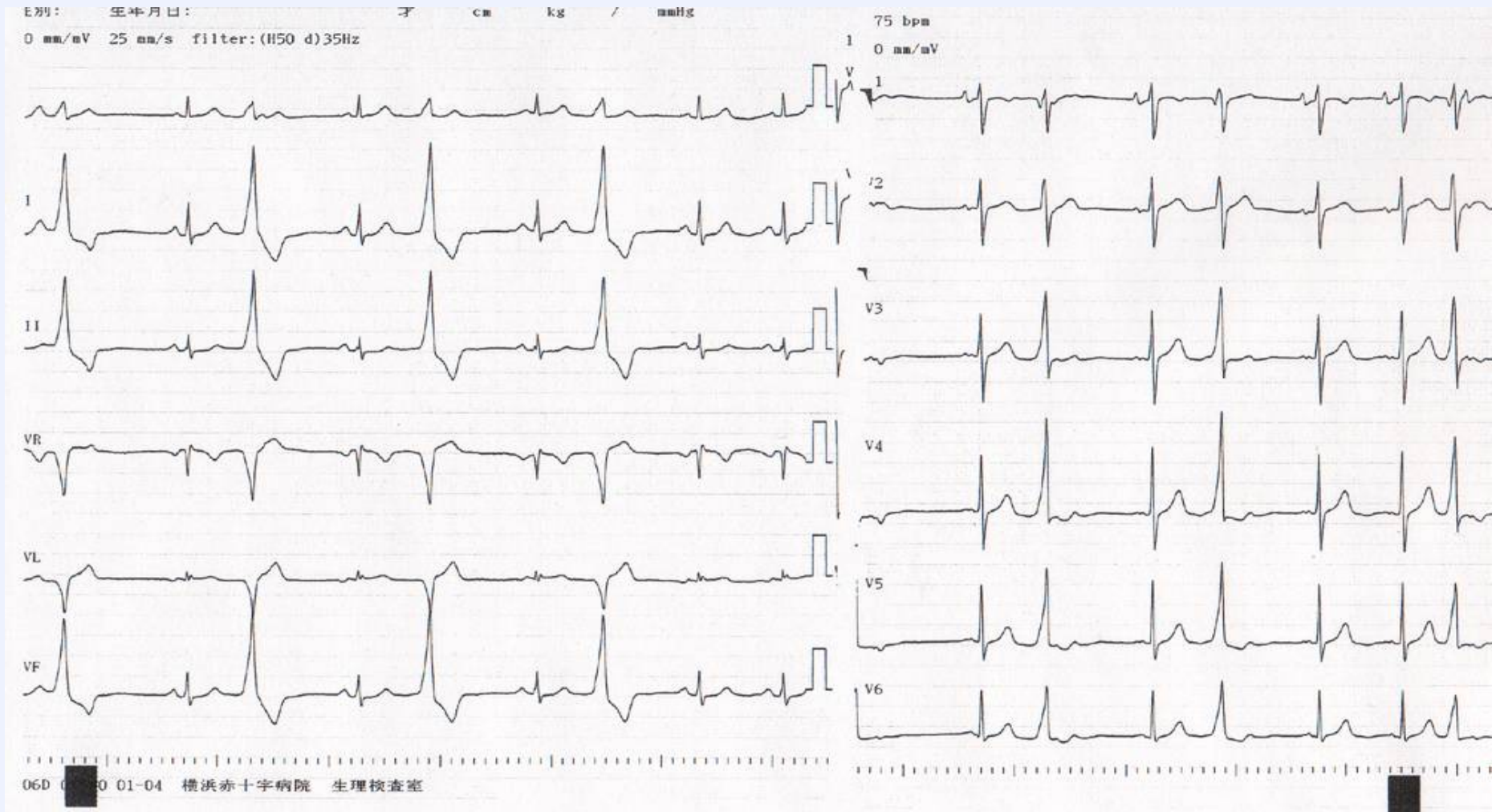
### *Case 1-5*

- 症例:T. T. 76歳 女性
- 現病歴:動悸を訴え近医受診し、frequent PVC'sにてカテーテルアブレーション目的にて当科紹介。
- ホルター心電図:34700beats/day
- short run(+), VT(-)
- 2DE:mild AR




# CCT 2004 Ablation Live Case Demonstrations

## Yokohama Red Cross Hospital



CASE 5 12ECG-NSR




## CCT 2004 Ablation Live Case Demonstrations

### *Yokohama Red Cross Hospital*

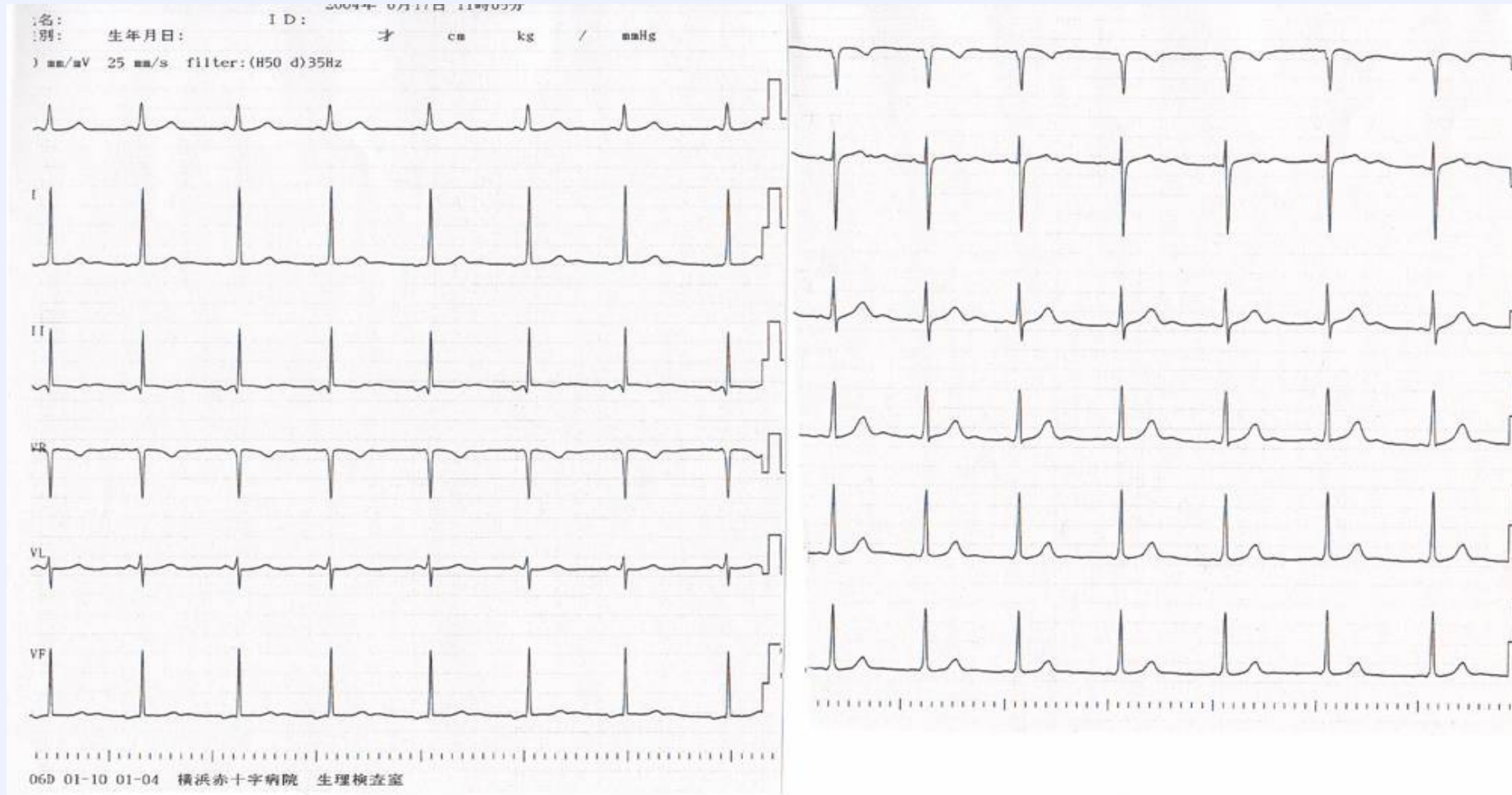
#### *Case 1-6*

- 症例：A. T. 25歳女性
- 現病歴：学童期にWPW指摘されるも動悸発作なきたため放置していた。2年前にPSVT発作あり。今回喀血あり当院呼吸器受診。特発性と診断。WPW根治を望んだためカテーテルアブレーションとなった。



# CCT 2004 Ablation Live Case Demonstrations

## Yokohama Red Cross Hospital



CASE 6 12ECG-NSR