


CCT 2004

CCT 2004 Live Case Demonstrations –Surgical–

高橋病院分



CCT 2004

CCT 2004 Live Case Demonstrations –Surgical-

Takahashi Hospital

Case 2-1 I.S. 47 y.o. male

Procedure: OPCAB

Diagnosis: OMI, AP

Present illness:

'04.9 Refer to Takahashi hospital due to the positive of the exercise ECG in other hospital.

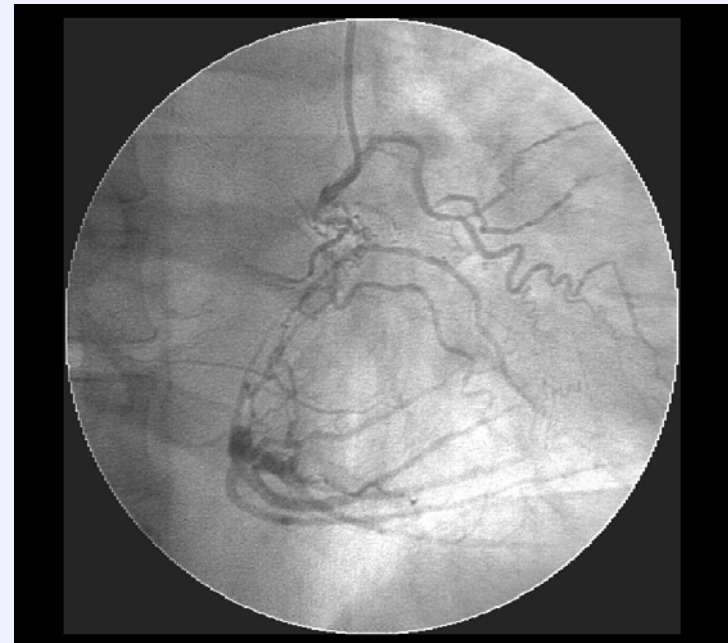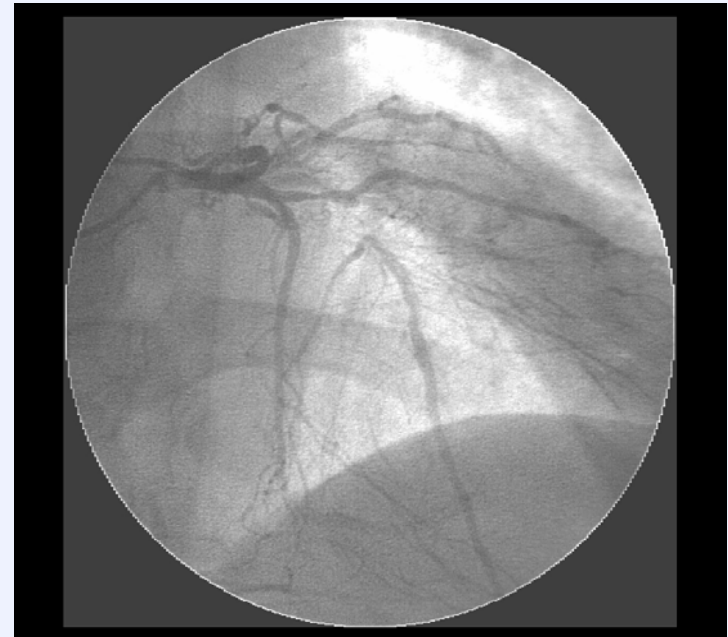Coronary Risk Factor:


HL, smoking

Final CAG Findings: '04.9.28

CAG: #7 100%, #13 100%, #1 100%

LVEF 39.4%





CCT 2004 Live Case Demonstrations –Surgical-

Takahashi Hospital

CCT 2004

Case 2-2 K.Y. 61 y.o. male

Procedure: OPCAB

Diagnosis: **OMI, AP**

Present illness:

'03.6.4 AMI

Seg. 6 100→0% (Φ3.5mm stent)

'04.2.9 CAG Seg. 6 90% (ISR)

Coronary Risk Factor:

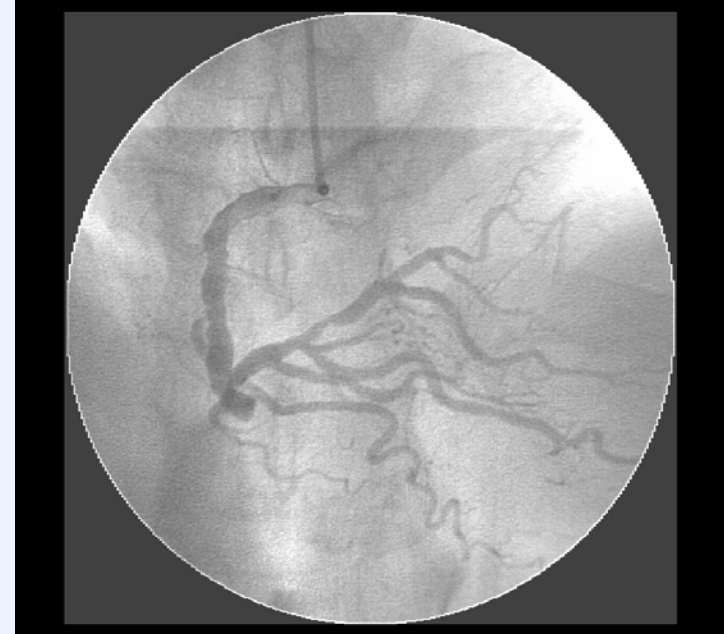
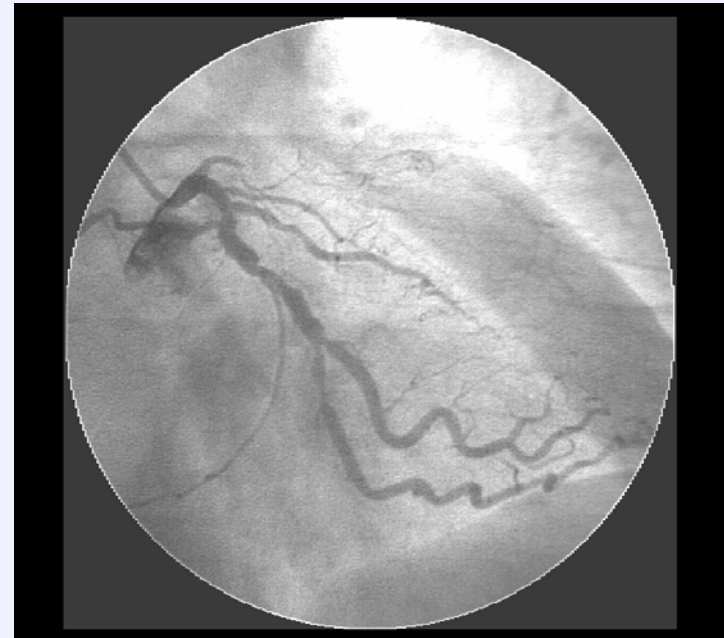
HL


Final CAG Findings: '04.8.16

CAG: #6 100%, #14,15 75%,

#4PL 75%

LVEF 64.1%





CCT 2004

CCT 2004 Live Case Demonstrations –Surgical-

Takahashi Hospital

Case 2-3 Y.Y. 64 y.o. male

Procedure: OPCAB

Diagnosis: AP

Present illness:

'02.11.23 AP attack

PCI Seg. 6 90→0%(Φ3.5mm stent)

'03.12.22 follow up CAG

PCI Seg. 7 90→0%(Φ3.0mm stent)

Coronary Risk Factor:

DM, HL

Final CAG Findings: '04.10.7

CAG: #7 75%, #13~15 75%

LVEF 68%

