


CCT 2004

CCT 2004 Live Case Demonstrations –Surgical–

豊橋ハートセンター分



CCT 2004

CCT 2004 Live Case Demonstrations –Surgical-

Toyohashi Heart Center

Case 1-1 S.U. 65 y.o. male

Procedure: OPCAB

Diagnosis: OMI

Present illness:

'04.~ Chest discomfort

Coronary Risk Factor:

Hypertension

Final CAG Findings: '04.9.29

LVG: Seg. 4 hypokinesis, Seg. 5,6 akinesis

EDVI 90 ml/m², ESVI 44 ml/m²,

LVEF: 50%, MR none

CAG: # 1 75%, #2 100%, #5 75%, #6 90%,

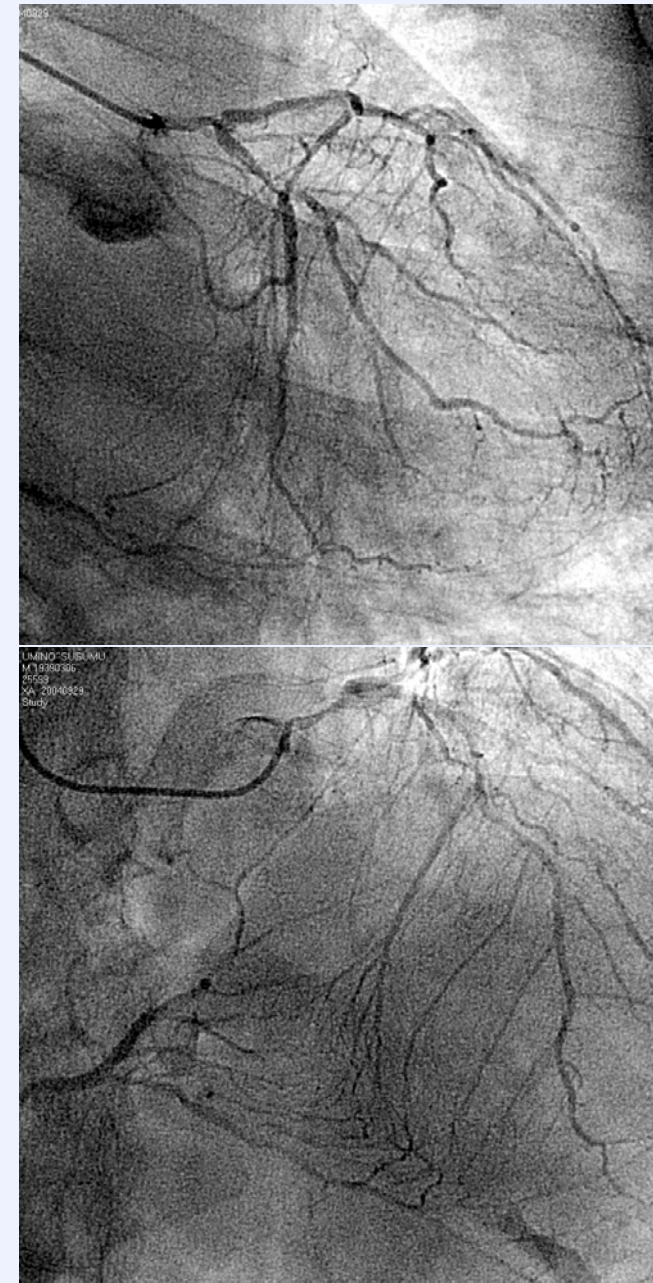
#7 75%, #9 90%, #11 90%, #13 90%,


#14 90%, #15 90%

Hemodynamic study:

PAWP 20 mmHg, PA 38/17 mmHg,

CI 3.20 l/min/m²





CCT 2004

CCT 2004 Live Case Demonstrations –Surgical-

Toyohashi Heart Center

Case 1-2 H.M. 65 y.o. female

Procedure: AVR

Diagnosis: AR

Present illness:

'04.~ dyspnea on exertion

Coronary Risk Factor:

Hypertention, Hyperlipidemia

Final CAG Findings: '04.3.25

LVG: normal wall motion

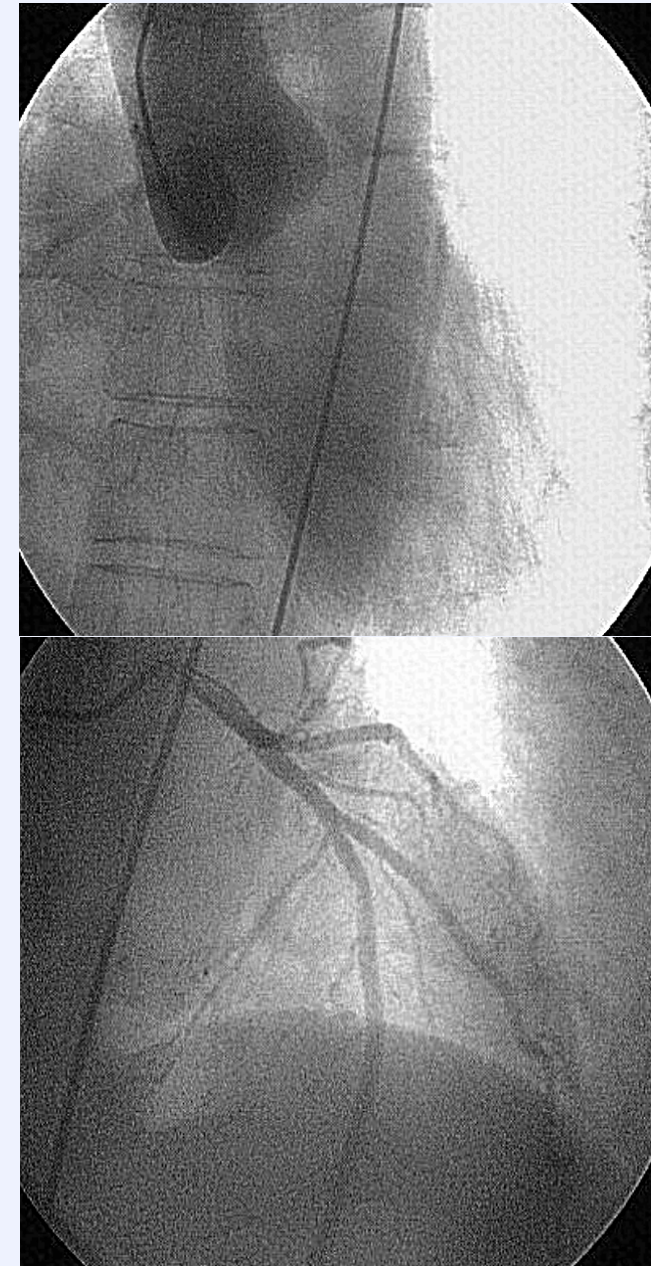
AoG: AR 4/4


CAG: no significant stenosis

Hemodynamic study:

PAWP 18 mmHg, PA 45/16 mmHg

CI 5.36 l/min/m²





CCT 2004 Live Case Demonstrations –Surgical-

Toyohashi Heart Center

CCT 2004

Case 1-3 K.K. 54 y.o. male

Procedure: MVP

Diagnosis: MR, Paf

Present illness:

'02.~ dyspnea on exertion

Coronary Risk Factor:

Hypertention

Final CAG Findings: '

LVG: LV wall motion normal

EDVI 102 ml/m², ESVI 46 ml/m²,

LVEF 55 %, MR 3/4

CAG: no significant stenosis

Hemodynamic study:

PAWP 33 mmHg, PA 76/37 mmHg

CI 4.66 l/min/m²

