



## CCT 2004 Live Case Demonstrations

*Toyohashi Heart Center*

CCT 2004

***Case 2-1 T. T. 63 y.o. male***

**Target Lesion: LMT**

**Diagnosis: OMI, AP, AAA**

**Present illness:**

- '91. Stent (RCA AMI)
- '04.7.13 Stent (RCA instent occlusion)  
Cypher, Express II
- '04.10.4 POBA (PL ISR, PD)

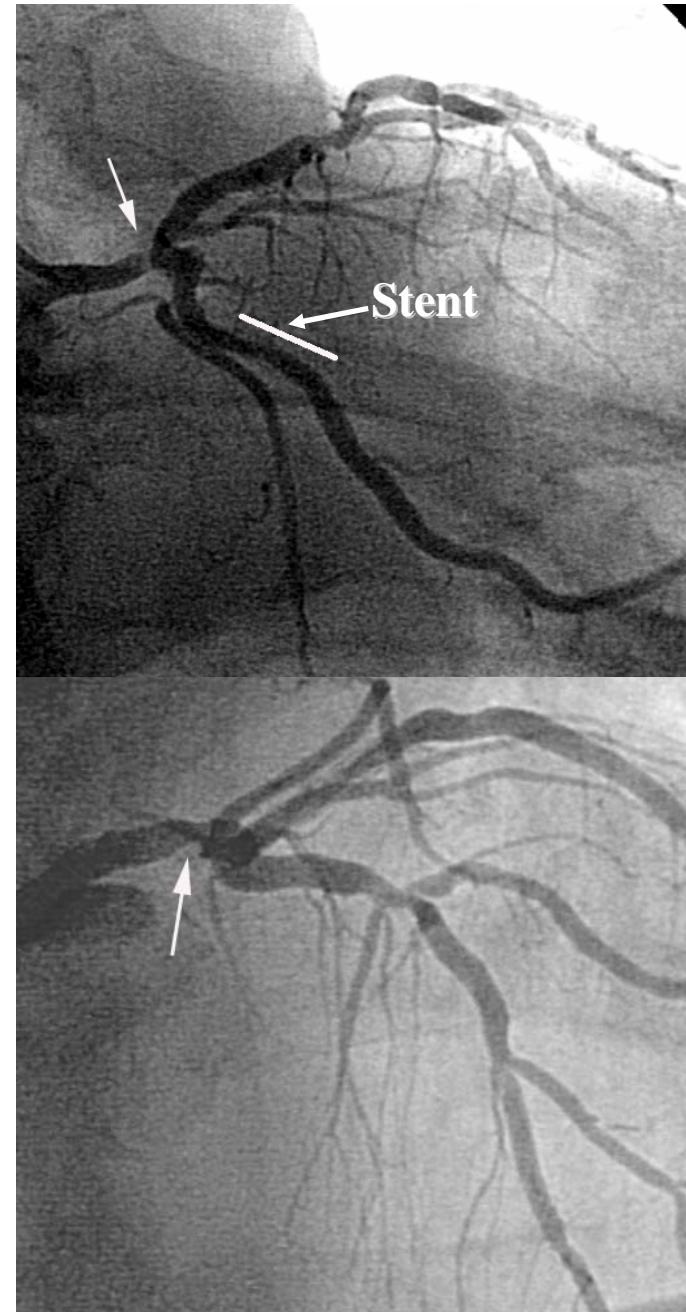
**Coronary risk factor:**

HT

**Final CAG findings: '04.7.13**

**LVEF: 41%**

**CAG: LMT 75%, mid LAD 75%, D1 75%**





CCT 2004

## CCT 2004 Live Case Demonstrations

*Toyohashi Heart Center*

**Case 2-2 U. H. 64 y.o. male**

**Target Lesion: Distal RCA (CTO)**

**Diagnosis: OMI**

**Present illness:**

'01.1.~ AP

CABG (2SVGs to LAD, RCA PD&PL)

CABG (SVG to PL)

'04.1.3 Cypher for LMT, Bx for dist. LCx

'04.8.31 Cypher for Bx-ISR

unsuccessful PCI for RCA-CTO

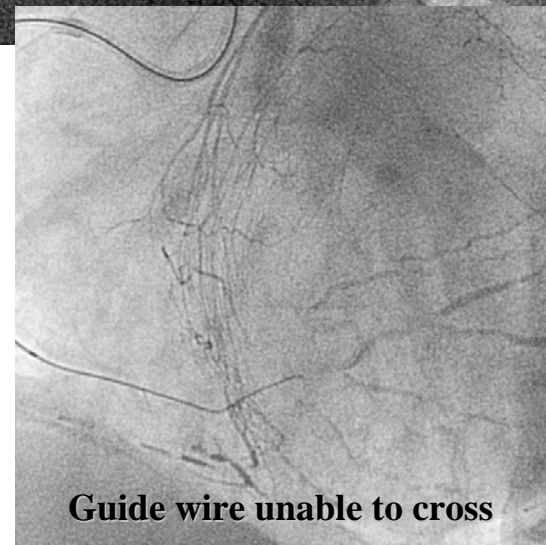
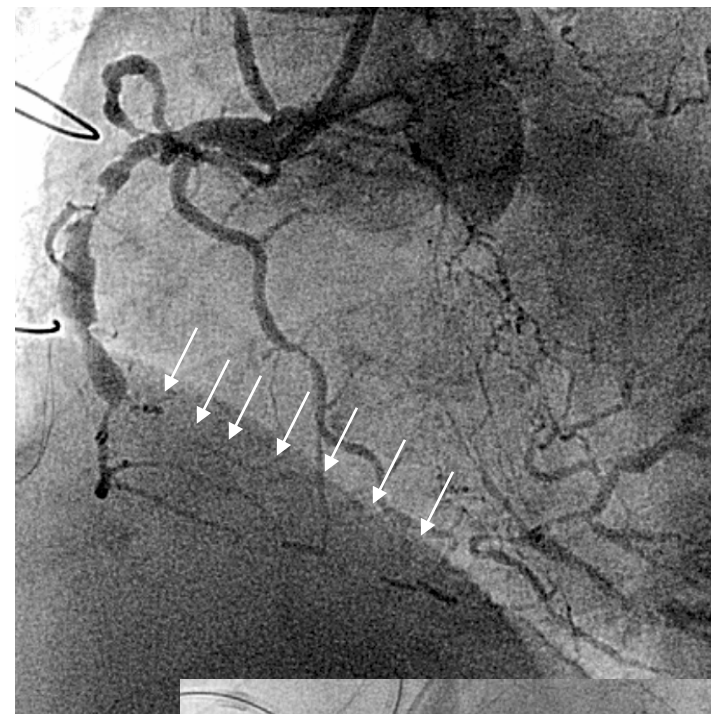
**Coronary risk factor:**

none

**Final CAG findings: '04.8.31**

LVG: not done

CAG: prox. RCA 90%, distal RCA 100%,  
prox. LAD 100%, HL 100%, OM 90%



Guide wire unable to cross



## CCT 2004 Live Case Demonstrations

*Toyohashi Heart Center*

CCT 2004

***Case 2-3 T. Y. 74 y.o. male***

***Target Lesion: Ostial LCx***

**Diagnosis: OMI**

**Present illness:**

- '03.12.15 Stent (*RCA BxVelocity*)  
Stent (*LAD Duraflex*)
- '04.1.13 Rotablator (*LCX*)

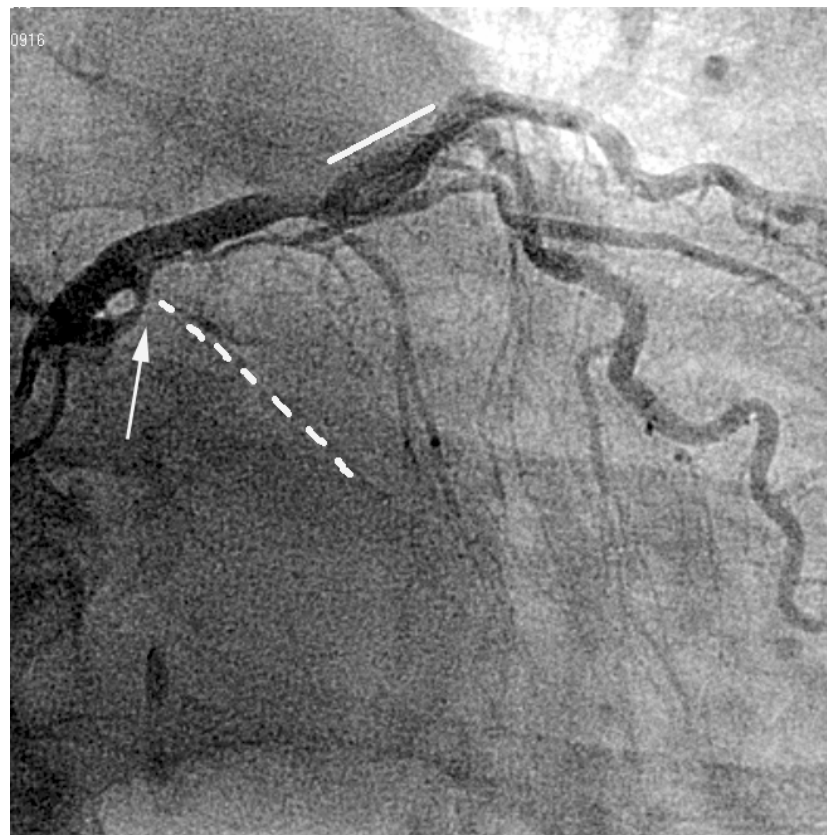
**Coronary risk factor:**

**HT, hyperlipidemia**

**Final CAG findings: '04.9.16**

**LVEF: 24%**

**CAG: *prox. LCx* 100%**





## CCT 2004 Live Case Demonstrations

*Toyohashi Heart Center*

CCT 2004

***Case 2-4 H. N. 67 y.o. male***

***Target Lesion: CIA, Mid RCA***

**Diagnosis: ASO, AP**

**Present illness:**

**Intermittent claudication (Fontaine-III)**

**ABI (Rt.:1.08, Lt.: 0.65)**

**Coronary risk factor:**

**HT**

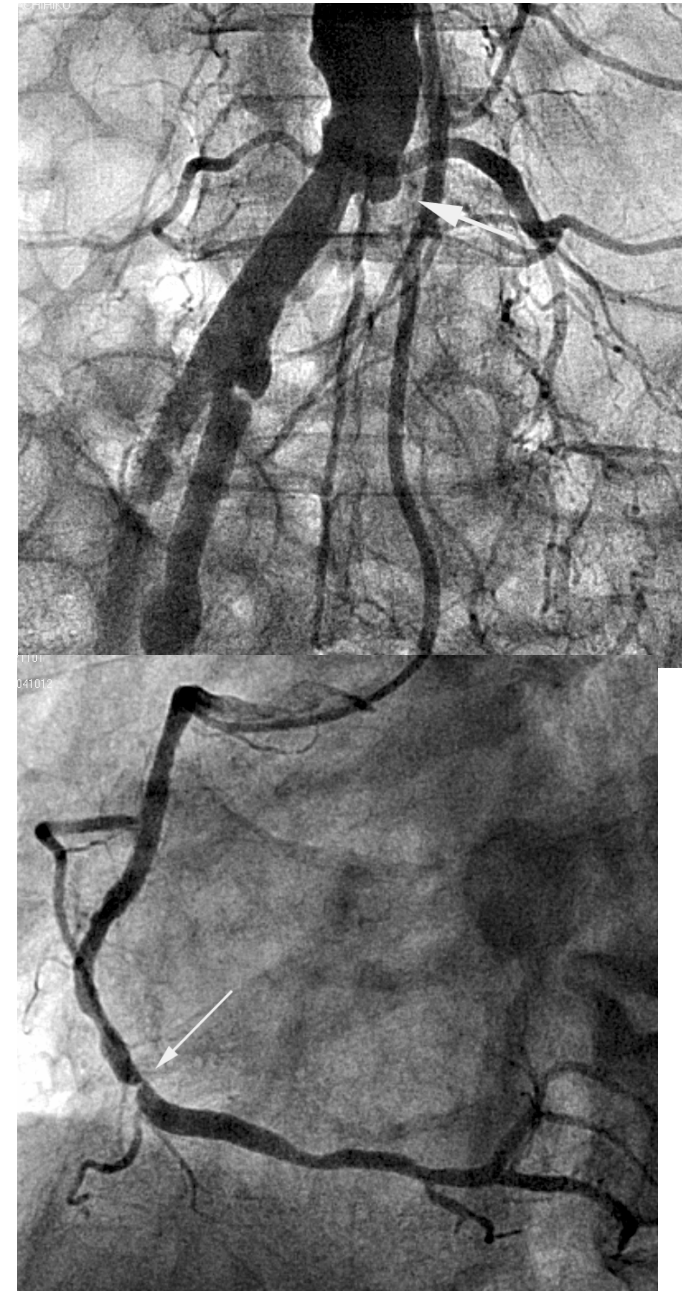**Final CAG findings: '04.10.13**

**LVEF: 63%**

**CAG: *mid RCA 75%*,**

**AOG: *lt. CIA 100%*,**

***rt. popliteal A. 75%***





## CCT 2004 Live Case Demonstrations

*Toyohashi Heart Center*

CCT 2004

*Case 2-5 H. K. 77 y.o. male*

*Target Lesion: Ostial LAD*

**Diagnosis: OMI, AP**

**Present illness:**

'04.9.4 dizziness, syncope

'04.9.10 ischemia by TI-SPECT

**Coronary risk factor:**

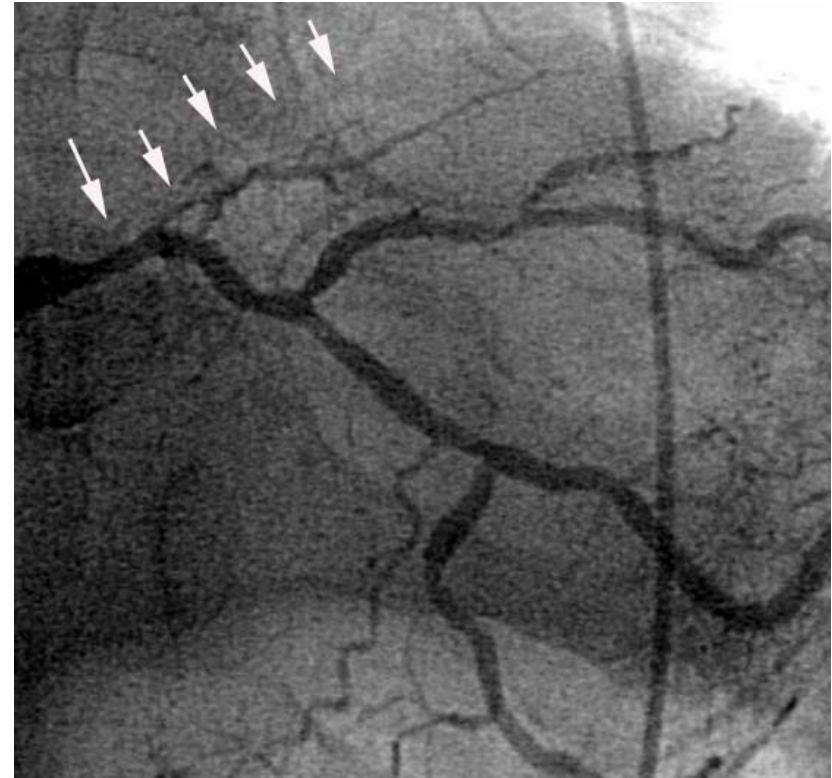
HT, DM, hyperlipidemia

**Final CAG findings: '04.9.16**

**LVEF: 48%**

**CAG: mid RCA 75%, distal RCA 90%, PL 99%**

**LMT 75%, ostial LAD 100%**





CCT 2004

## CCT 2004 Live Case Demonstrations

*Toyohashi Heart Center*

***Case 2-6 S. K. 58 y.o. female***

***Target Lesion: Mid RCA (CTO)***

**Diagnosis: AP**

**Present illness:**

'04.9~ morning chest oppression

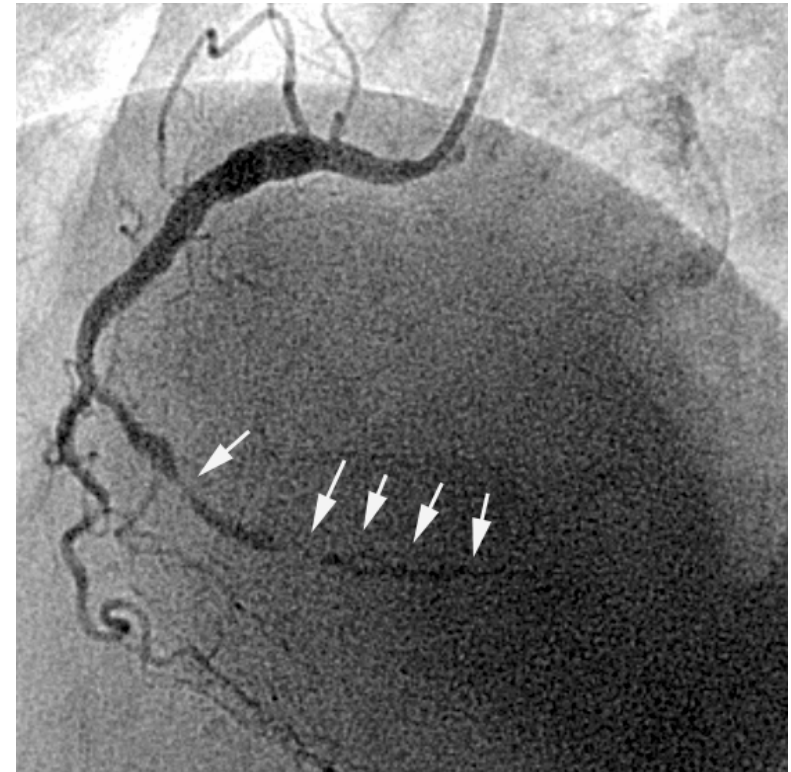
**Coronary risk factor:**

**HT**

**Final CAG findings: '04.9.29**

**LVEF: 60%**

**CAG: *mid RCA 75%, distal RCA 100%***





CCT 2004

## CCT 2004 Live Case Demonstrations

*Toyohashi Heart Center*

*Case 2-7 M. J. 74 y.o. male*

*Target Lesion: Ostial LAD*

**Diagnosis: OMI, AP**

**Present illness:**

'04.6.6 CB (*LAD AMI*)

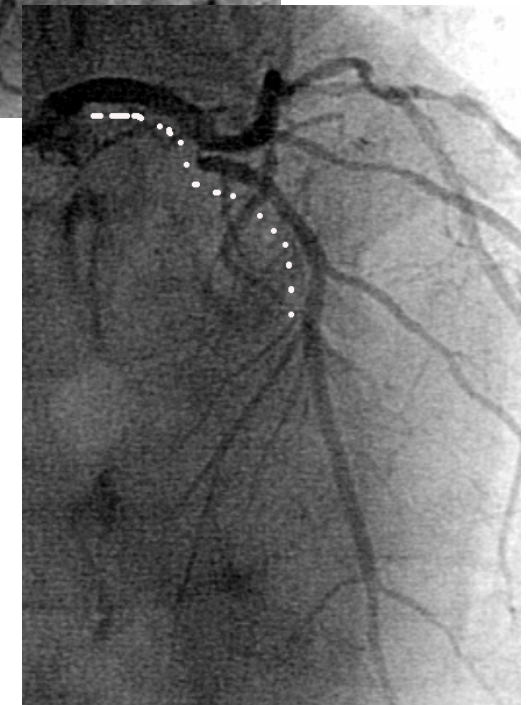
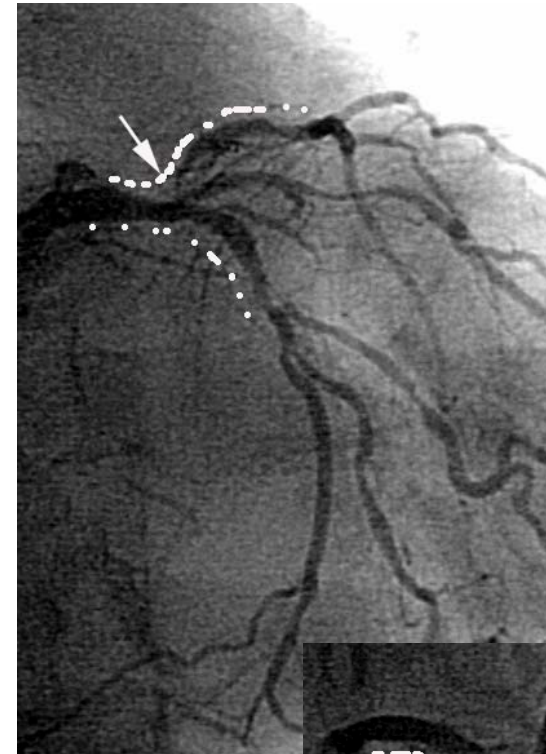
**Coronary risk factor:**

DM, HT

**Final CAG findings: '04.10.4**

LVEF: 54%

*CAG: ostial LAD 90%, mid PD 90%  
proximal OM 90%, mid HL 75%*





## CCT 2004 Live Case Demonstrations

*Toyohashi Heart Center*

CCT 2004

*Case 2-8 E. S. 54 y.o. female*

*Target Lesion: Ostial LAD*

**Diagnosis: AP**

**Present illness:**

'99.10~ EA

'04.10.2 EA worsening

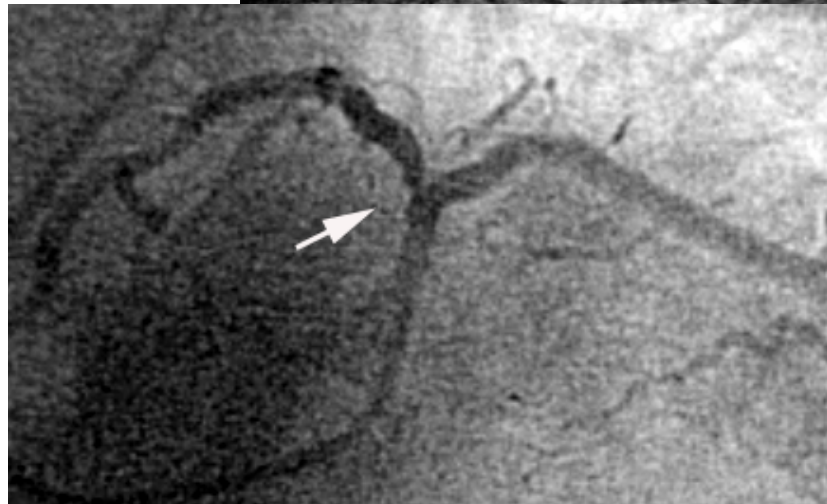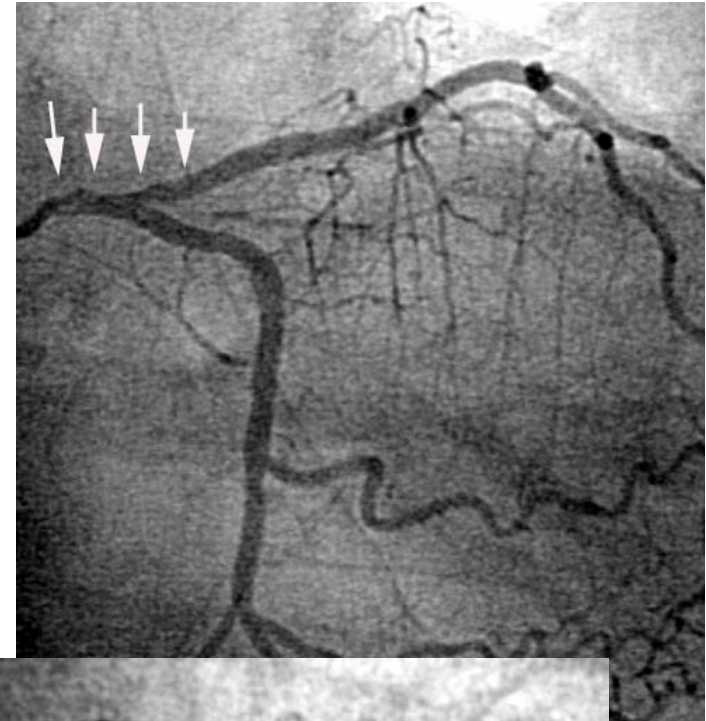
**Coronary risk factor:**

Hyperlipidemia

**Final CAG findings: '04.10.4**

LVEF: 59%

**CAG: LMT 50%, ostial LAD 75%, ostial LCx 50%**







CCT 2004

## CCT 2004 Live Case Demonstrations

*Toyohashi Heart Center*

***Case 2-9 T. K. 78 y.o. male***

***Target Lesion: Rt. CIA, Rt. SFA***

**Diagnosis: ASO**

**Present illness:**

**Intermittent claudication (Fontaine-III)**

**ABI (Rt.: 0.67, Lt.: 0.66)**

**'04.10.4 Stent (*lt. SFA*, LUMINEXX)**

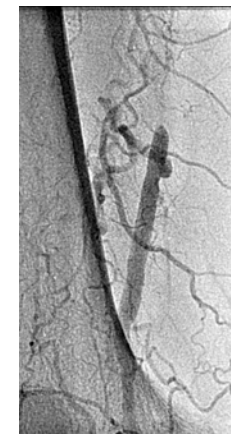
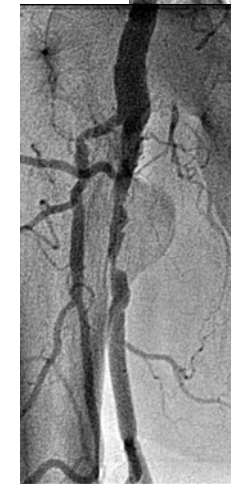
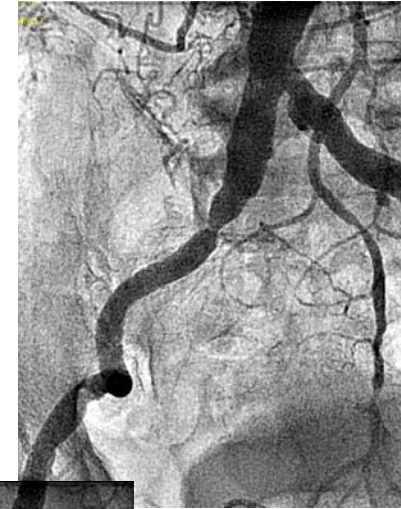**Coronary risk factor:**

**HT**

**Final CAG findings: '04.10.4**

**AOG: rt. CIA 75%, rt. SFA 100%**

**(lt. CIA 75%, lt. SFA 100%)**





CCT 2004

## CCT 2004 Live Case Demonstrations

*Toyohashi Heart Center*

*Case 2-10 N. N. 52 y.o. male*

*Target Lesion: Ostial LAD*

**Diagnosis: UAP**

**Present illness:**

'04.9.~ EA

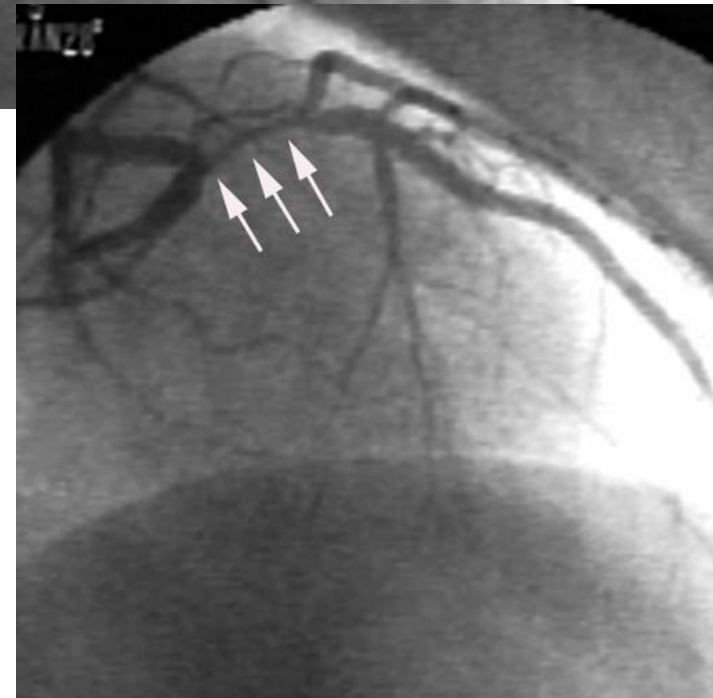
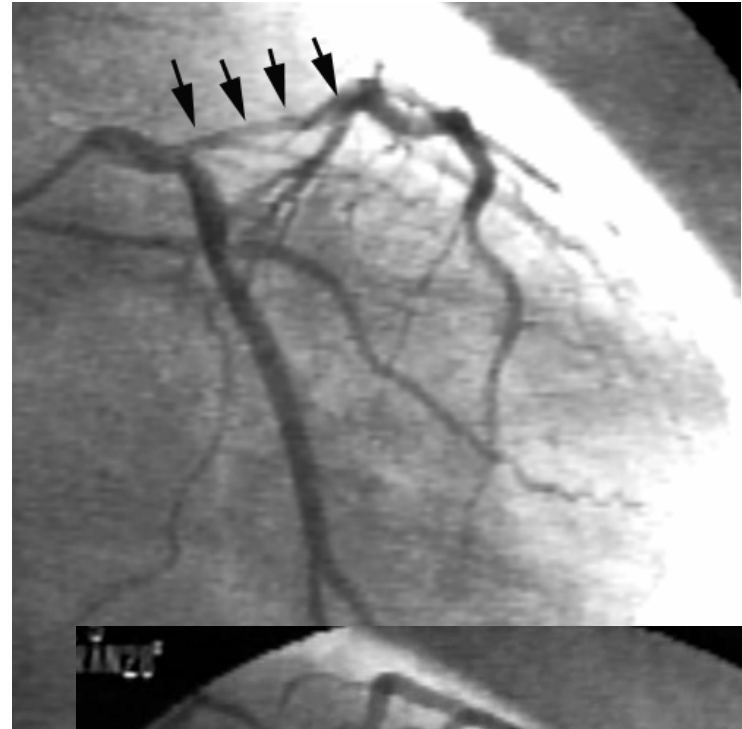
**Coronary risk factor:**

Smoking

**Final CAG findings: '04.10.4**

**LVG: no asynergy**

**CAG: proximal LAD 90%**





CCT 2004

## CCT 2004 Live Case Demonstrations

*Toyohashi Heart Center*

***Case 2-11 K. N. 74 y.o. male***

***Target Lesion: LMT, Ostial LCx***

**Diagnosis: AP**

**Present illness:**

- '94.6.30 POBA (*LCx*)
- '98.6.12 Stent (*proximal RCA, gfx*)
- '98.3.18 POBA (*distal RCA, AMI*)

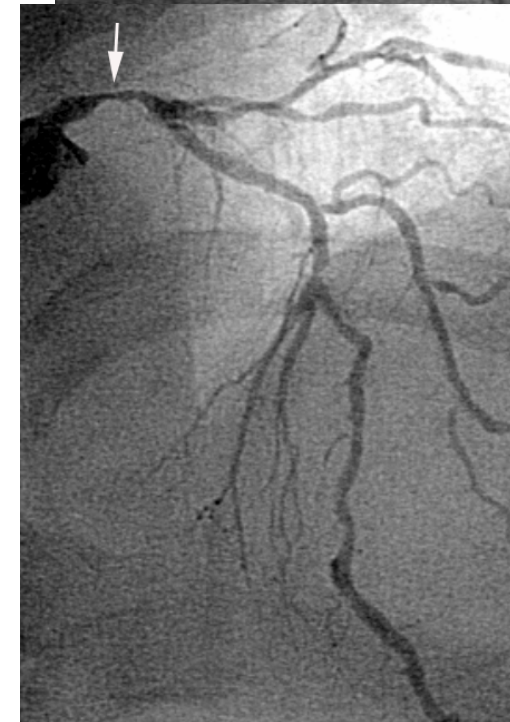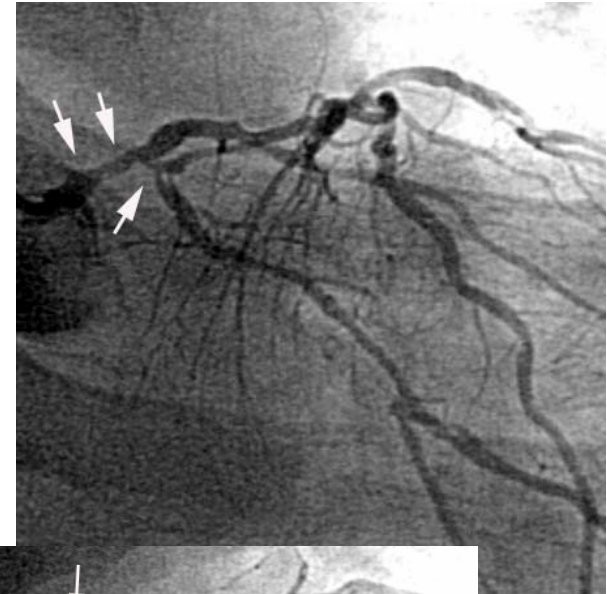
**Coronary risk factor:**

**HT**

**Final CAG findings: '04.10.8**

**LVEF: 59%**

**CAG: *LMT 90%, mid\_LAD 75%,  
ostial LCx 90%, mid LCx 75%***





CCT 2004

## CCT 2004 Live Case Demonstrations

*Toyohashi Heart Center*

*Case 2-12 Y. N. 61 y.o. female*

*Target Lesion: Ostial LAD*

**Diagnosis: AP**

**Present illness:**

'04.1.~ EA

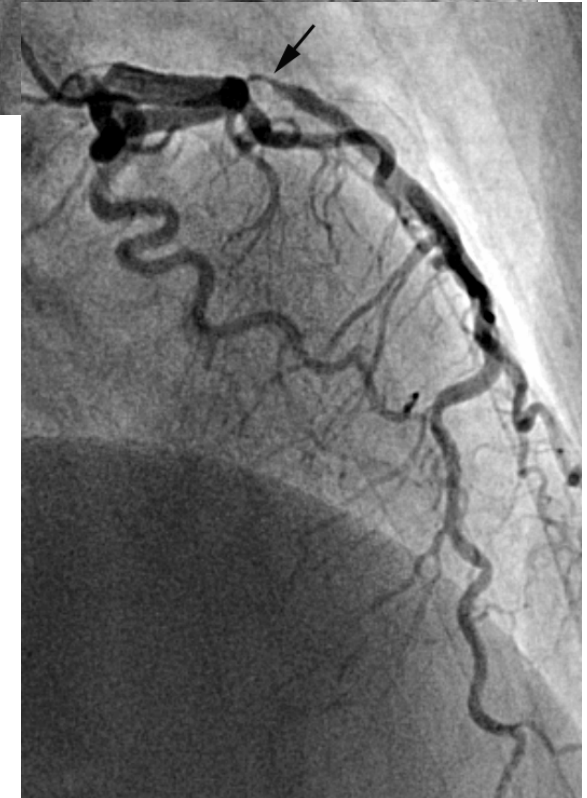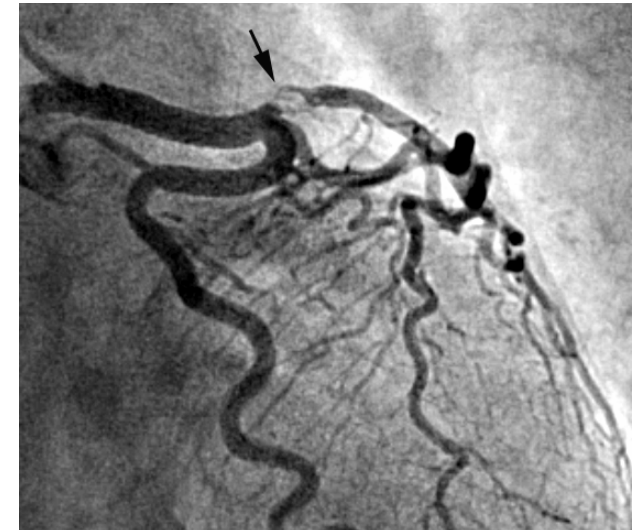**Coronary risk factor:**

HT

**Final CAG findings: '04.10.15**

**LVEF: 46%**

**CAG: *ostial LAD 90%***





## CCT 2004 Live Case Demonstrations

*Toyohashi Heart Center*

CCT 2004

***Case 2-13 Y. Y. 65 y.o. male***

**Target Lesion: LAD**

**Diagnosis: OMI, AP**

**Present illness:**

'02.11.11 POBA (*LAD, AMI*)

'03.6.18 CABG

(*LITA-LAD, RITA-rad.-OM, GEA-PD*)

'03.8.28 Rota+CB (*LAD*)

'03.10.8 Stent (*LMT, BxV*), CB (*LAD*)

**Coronary risk factor:**

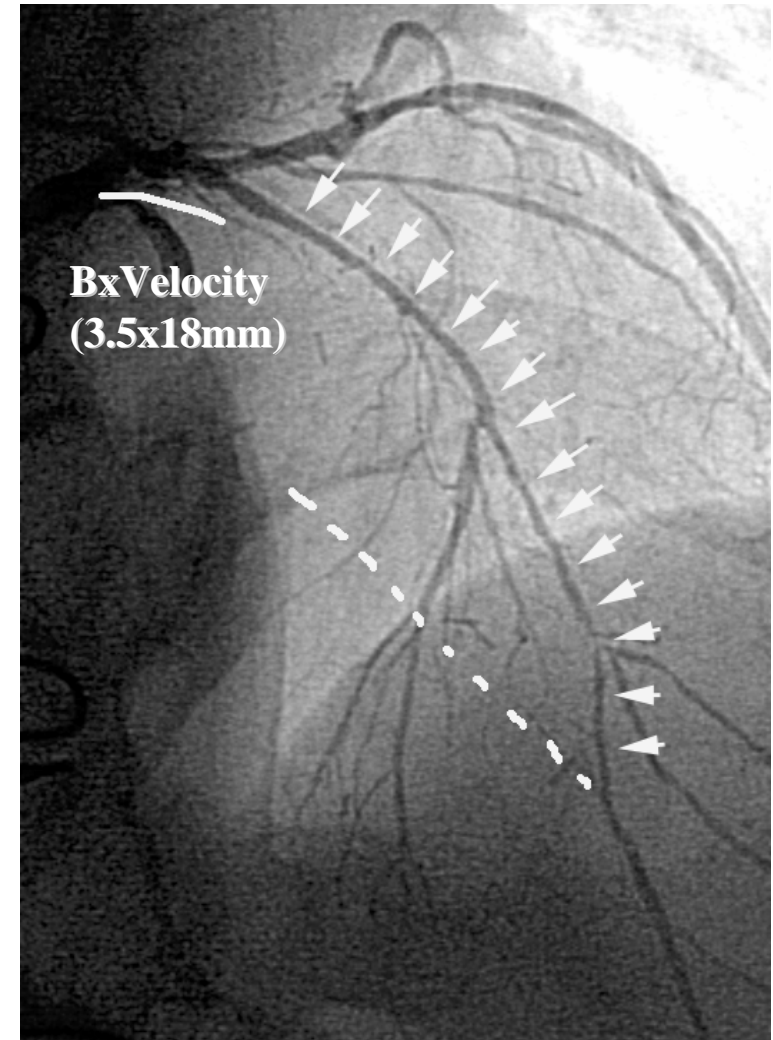
HT

**Final CAG findings: '04.10.8**

LVG: not done

CAG: *LAD 75-90%* (diffuse), *DI 100%*

*LITA 100%, RITA 100%, GEA 100%*





# CCT 2004 Live Case Demonstrations

*Toyohashi Heart Center*

CCT 2004

***Case 2-14 S. K. 58 y.o. male***

***Target Lesion: Dist. LCx (CTO)***

**Diagnosis: OMI, AP**

**Present illness:**

'02.3.22 POBA (*LAD, AMI*)

'02.5.15 DCA (*LAD reocclusion*)

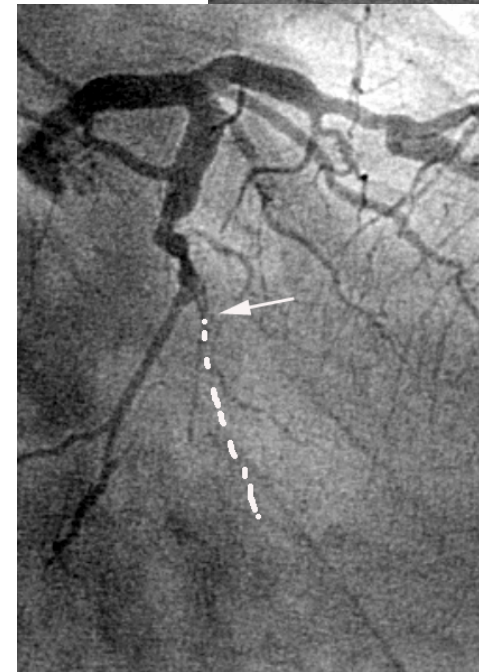
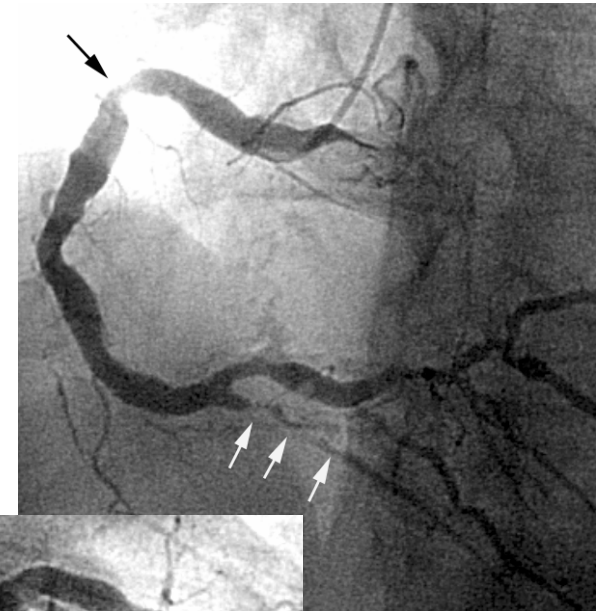
**Coronary risk factor:**

HT, hyperlipidemia

**Final CAG findings: '04.10.8**

**LVEF: 48%**

**CAG: *prox. RCA 75%, PD 99%,  
OM 100%, mid LAD 75%***





## CCT 2004 Live Case Demonstrations

*Toyohashi Heart Center*

CCT 2004

*Case 2-15 M. M. 60 y.o. male*

*Target Lesion: Prox. LCx*

**Diagnosis: AP**

**Present illness:**

'04.8.8 chest pain

'04.8.16 CAG

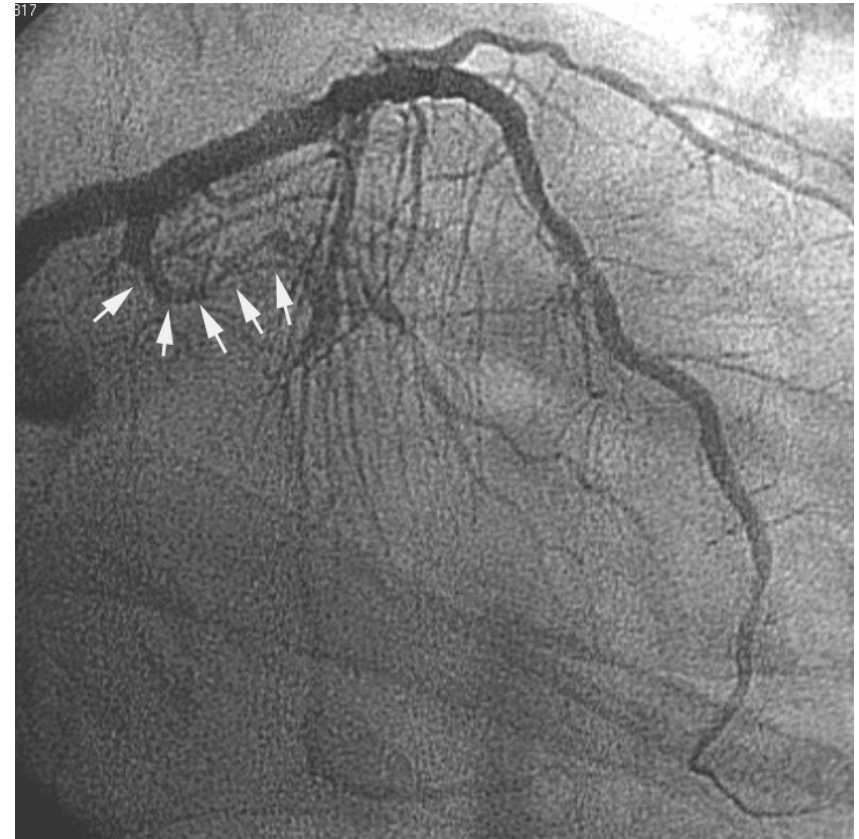
**Coronary risk factor:**

HT

**Final CAG findings: '04.8.16**

**LVEF: 64%**

**CAG: *proximal LCx 99% (bend)***





## CCT 2004 Live Case Demonstrations

*Toyohashi Heart Center*

CCT 2004

***Case 2-16 T. M. 42 y.o. male***

***Target Lesion: prox. RCA***

**Diagnosis: OMI, AP**

**Present illness:**

'04.4.15 CB (LCX)

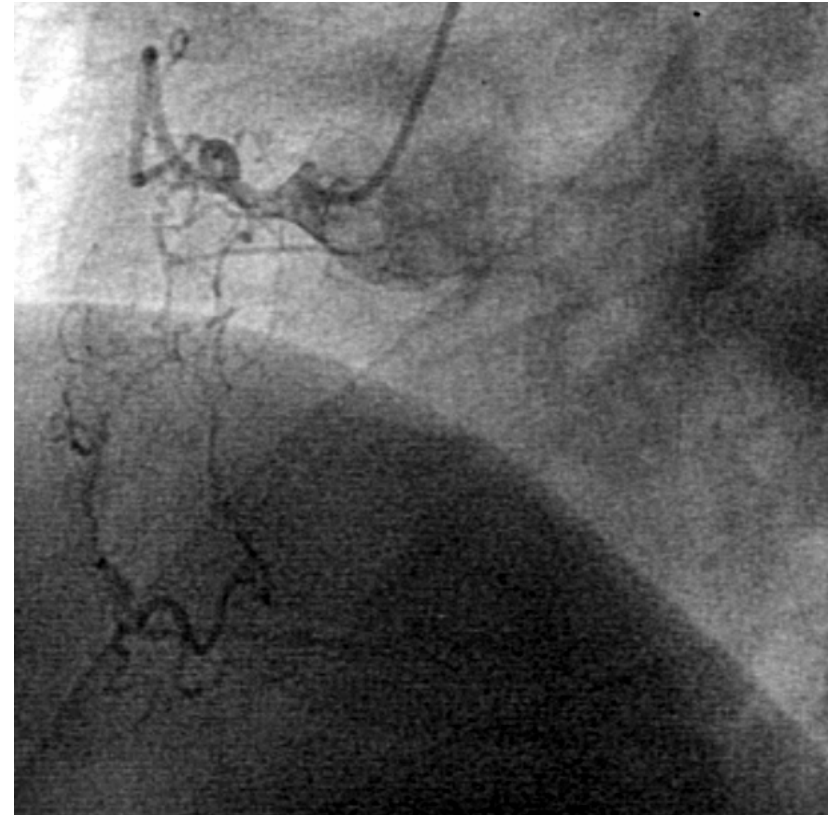
**Coronary risk factor:**

HT

**Final CAG findings: '04.4.12**

**LVEF: 42%**

**CAG: *prox. RCA 100%, (mid. LCX 75%)***







CCT 2004

## CCT 2004 Live Case Demonstrations

*Toyohashi Heart Center*

*Case 2-17 S. H. 82 y.o. male*

*Target Lesion: Ostial LAD*

**Diagnosis: OMI, AP**

**Present illness:**

- '04.4.19 CB (*mid LAD ISR*)
- '04.4.20 POBA (*LCx*)
- '04.8.27 Cypher (*RCA-CTO, dist. LCx*)
- '04.9.14 Cypher (*RCA-reocclusion*)

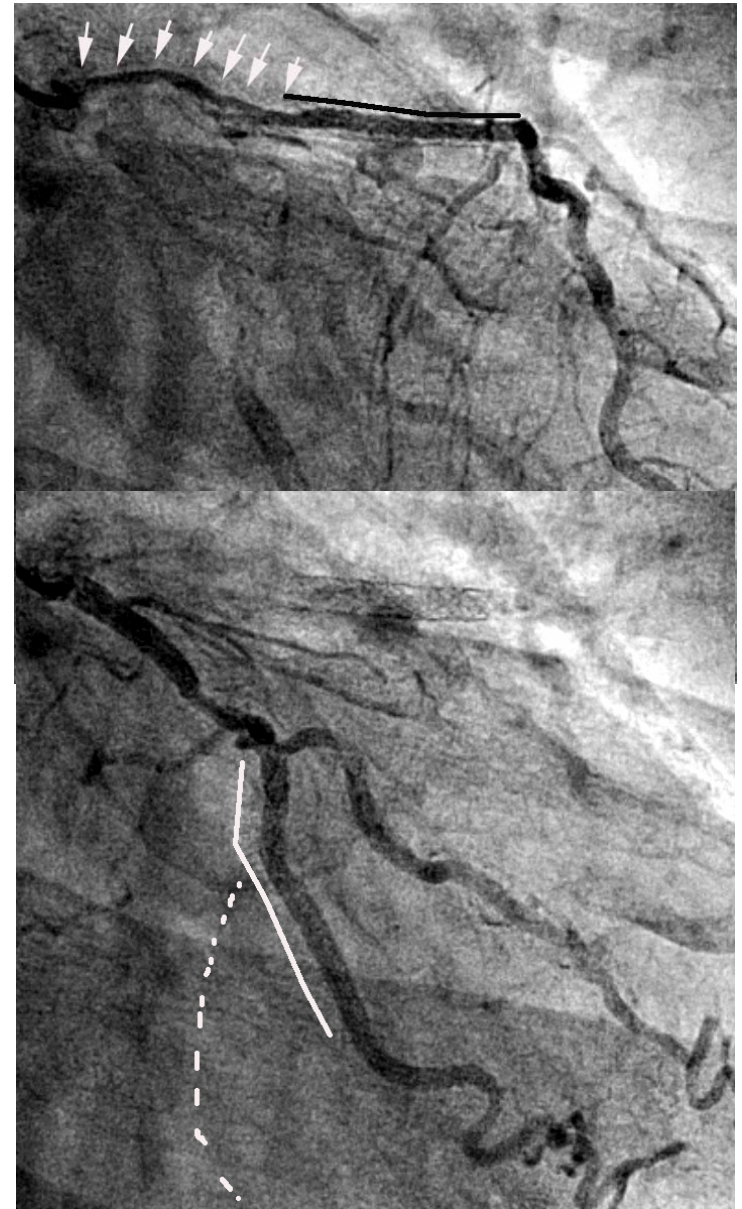
**Coronary risk factor:**

none

**Final CAG findings: '04.9.17**

**LVG: none done**

**CAG: *ostial LAD 75%, mid LCX 75%, distal LCx 100%***





## CCT 2004 Live Case Demonstrations

*Toyohashi Heart Center*

CCT 2004

***Case 2-18 M. K. 82 y.o. male***

***Target Lesion: Ostial LAD***

**Diagnosis: EAP**

**Present illness:**

'03.9.29 Ablation (PSVT)

'04.10.14 Stent (*Prox. RCA* Cypher)

**Coronary risk factor:**

none

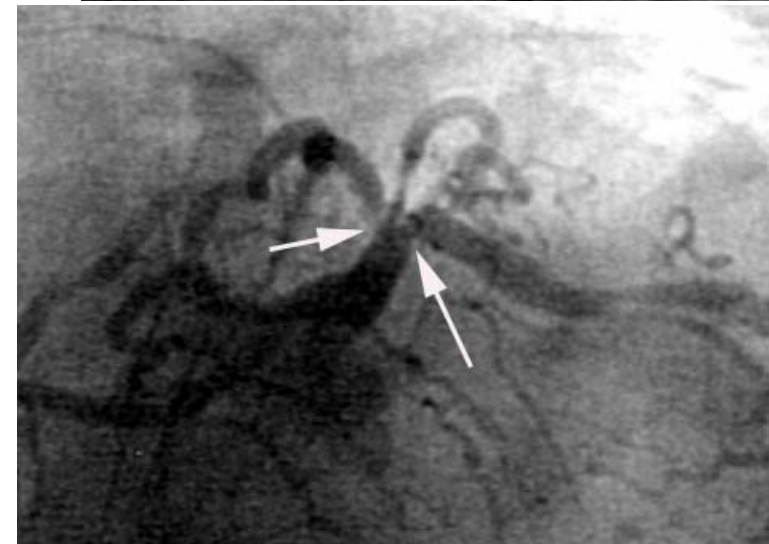
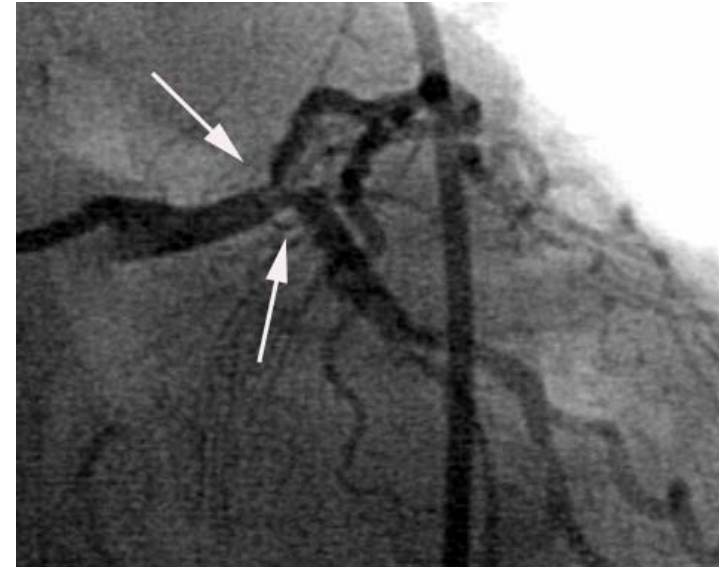
**Final CAG findings: '04.10.17**

**LVEF: 52%**

**CAG: *prox. RCA 75%, PD 75%,***

***LMT 50%, ostial LAD 75%, mid LAD 75%,***

***ostial LCX 50%, HL 75%, mid LCx 75%***





## CCT 2004 Live Case Demonstrations

*Toyohashi Heart Center*

CCT 2004

**Case 2-19** A. I. 66 y.o. female

**Target Lesion: Ostial LCx**

**Diagnosis: RMI**

**Present illness:**

- '04.10. AMI
- '04.10.7 Stent (*LMT & LAD*, Cypher)  
GW unable to cross (*LCx*)

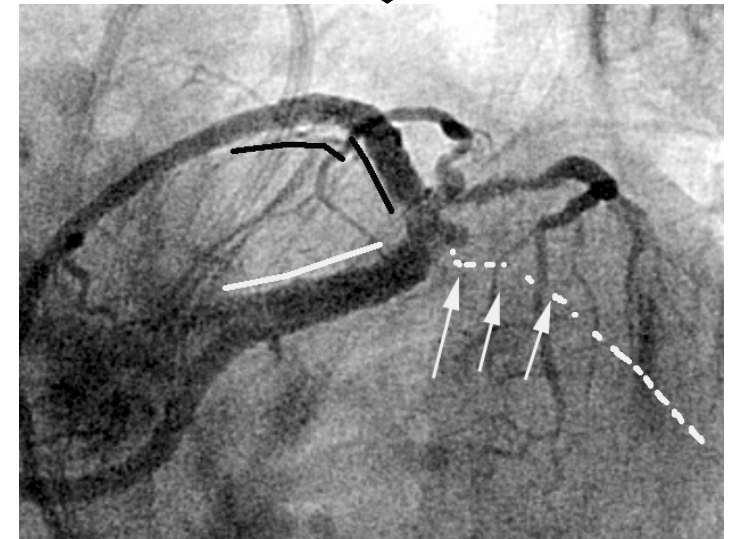
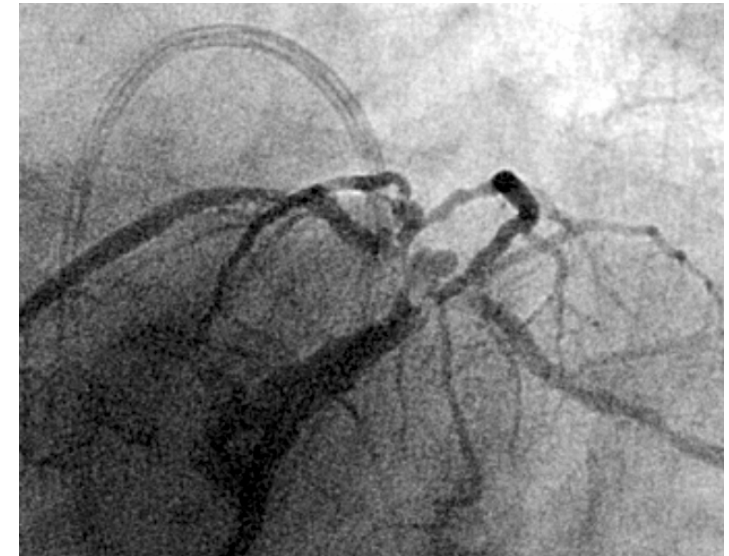
**Coronary risk factor:**

none

**Final CAG findings: '04.10.7**

**LVEF: 52%**

**CAG: *LMT 75%, ostial LAD 90%, mid LAD 90%,  
ostial LCx 90%***





## CCT 2004 Live Case Demonstrations

*Toyohashi Heart Center*

CCT 2004

***Case 2-20 T. N. 71 y.o. male***

***Target Lesion: LAD??***

**Diagnosis: OMI**

**Present illness:**

- '94.10.12 Guide wire unpass (*RCA-CTO*)
- '00.10.6 Guide wire unpass (*RCA-CTO*)
- '04.10.13 *LAD* stenosis suspected by MSCT

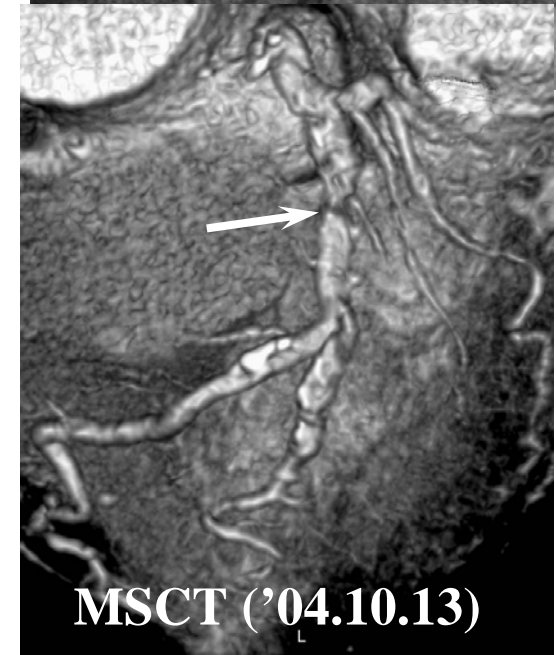
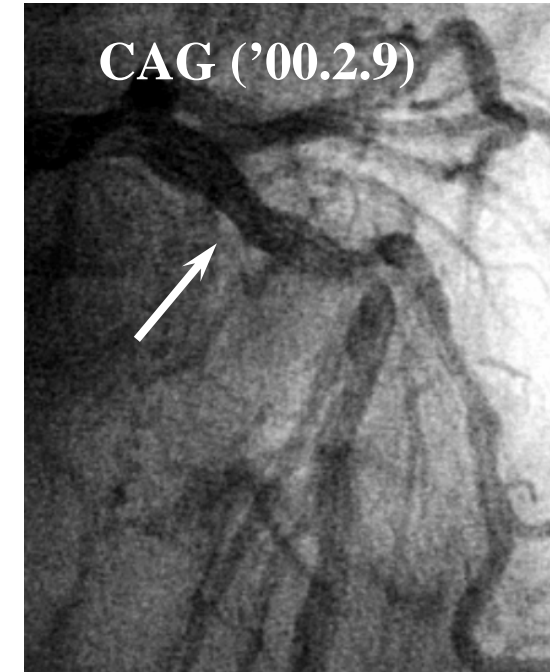
**Coronary risk factor:**

Smoking

**Final CAG findings: '00.2.9**

LVEF: 47%

CAG: *Prox. RCA* 100%,





## CCT 2004 Live Case Demonstrations

*Toyohashi Heart Center*

CCT 2004

***Case 2-21 N. O. 59 y.o. male***

***Target Lesion: Prox. RCA (CTO)***

**Diagnosis: OMI, AP**

**Present illness:**

'01.6.11 CABG: LITA-LAD  
RITA-RA-D1  
GEA-PD

'01.7.10 Stent (LCx, S670)

'03.4.30 POBA (LCx-ISR)

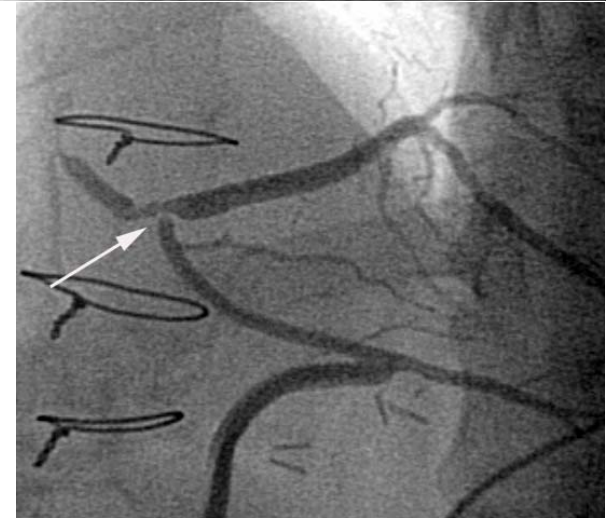
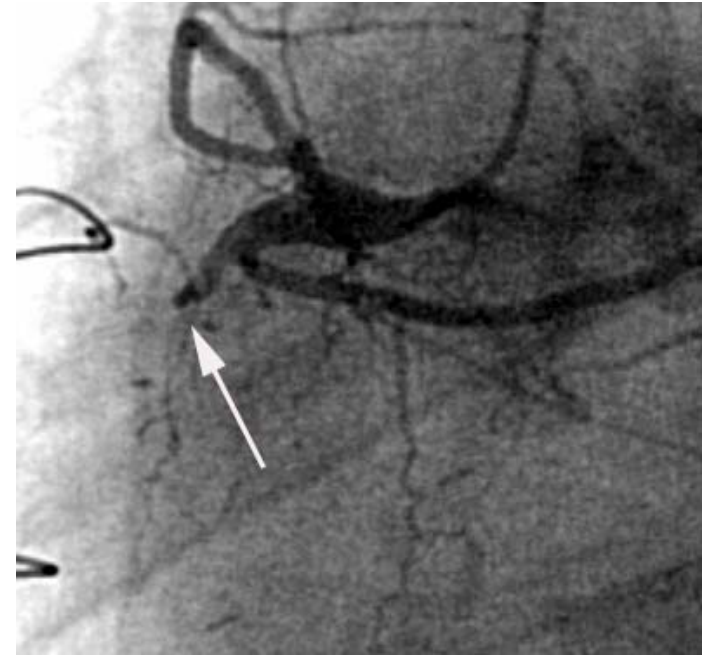
**Coronary risk factor:**

Smoking

**Final CAG findings: '04.8.25**

LVEF: 45%

CAG: *prox. RCA 100%, distal RCA 90%,  
LITA-LAD, GEA-PD patent, RITA-D1 100%*





CCT 2004

## CCT 2004 Live Case Demonstrations

*Toyohashi Heart Center*

*Case 2-22 S. I. 74 y.o. female*

*Target Lesion: Ostial RCA??*

*will be determined by MSCT*

**Diagnosis: AP**

**Present illness:**

'02.2.6 Stent (*ostial RCA, TriStar*)

'02.6.10 POBA (*RCA-ISR*)

**Coronary risk factor:**

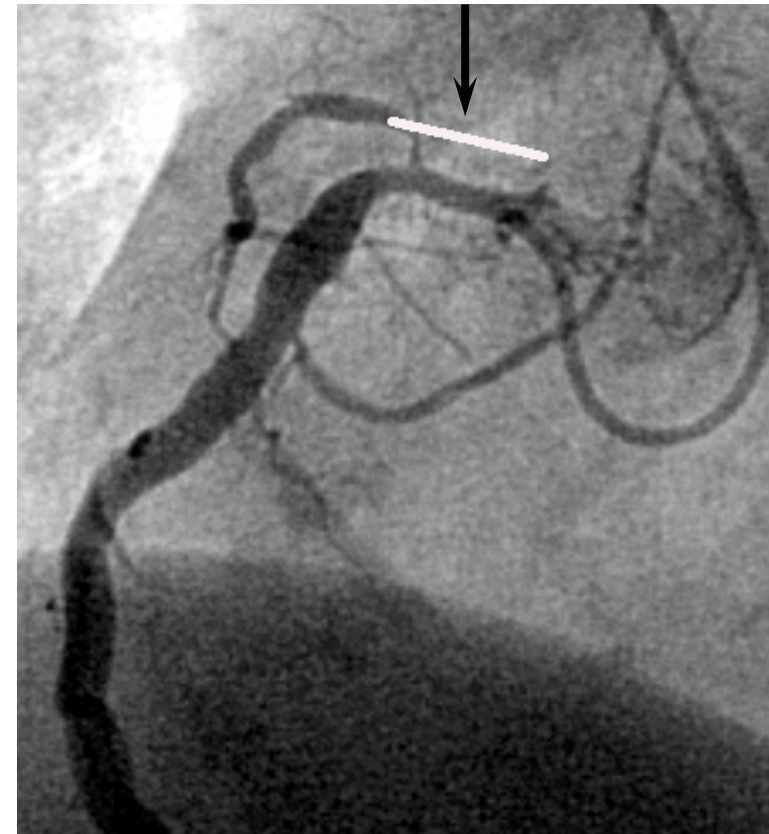
HT, hyperlipidemia

**Final CAG findings: '03.11.10**

**LVEF: 61%**

**CAG: *ostial RCA 75%, mid LAD 50%, mid LCX 50%***

**TriStar 4.0x13mm**





## CCT 2004 Live Case Demonstrations

*Toyohashi Heart Center*

CCT 2004

***Case 2-23 T. S. 74 y.o. female***

***Target Lesion: LMT***

**Diagnosis: OMI, AP**

**Present illness:**

'95.3.9 POBA (RCA)

'95.6.28 DCA (RCA)

'95.7.20 POBA (LAD)

'96.11.5 POBA (LCx)

**Coronary risk factor:**

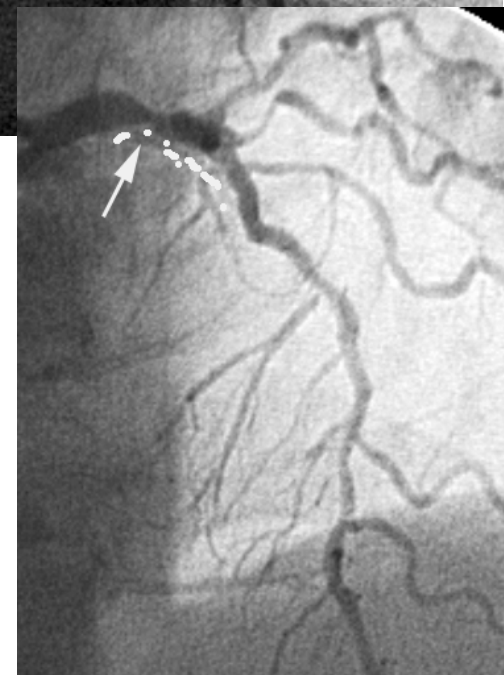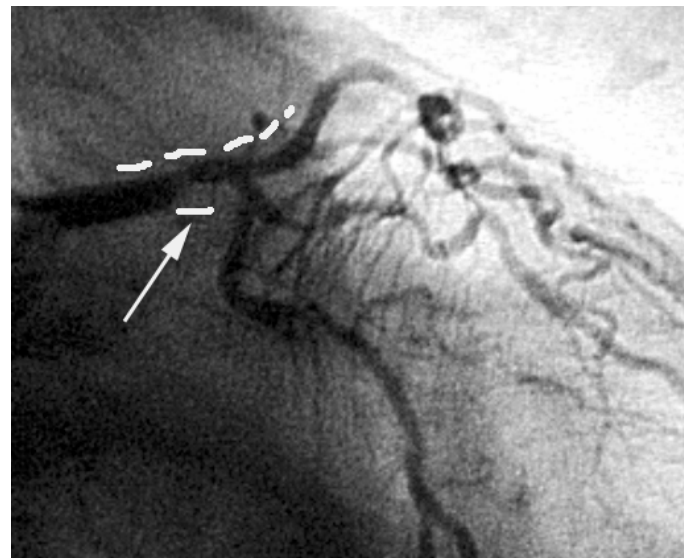
HT, hyperlipidemia

**Final CAG findings: '04.10.5**

LVEF: 58%

CAG: *LMT 75%, mid LAD 50%,*

*mid LCx 90%, prox. RCA 50%, PD 75%*





## CCT 2004 Live Case Demonstrations

*Toyohashi Heart Center*

CCT 2004

*Case 2-24 Y. H. 64 y.o. male*

*Target Lesion: Distal RCA??*

**Diagnosis: AP**

**Present illness:**

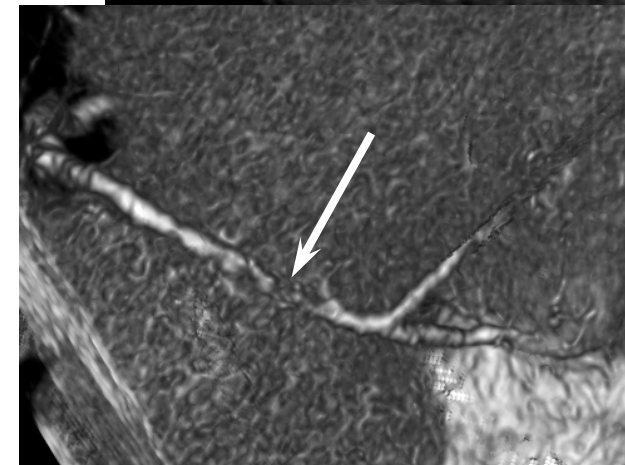
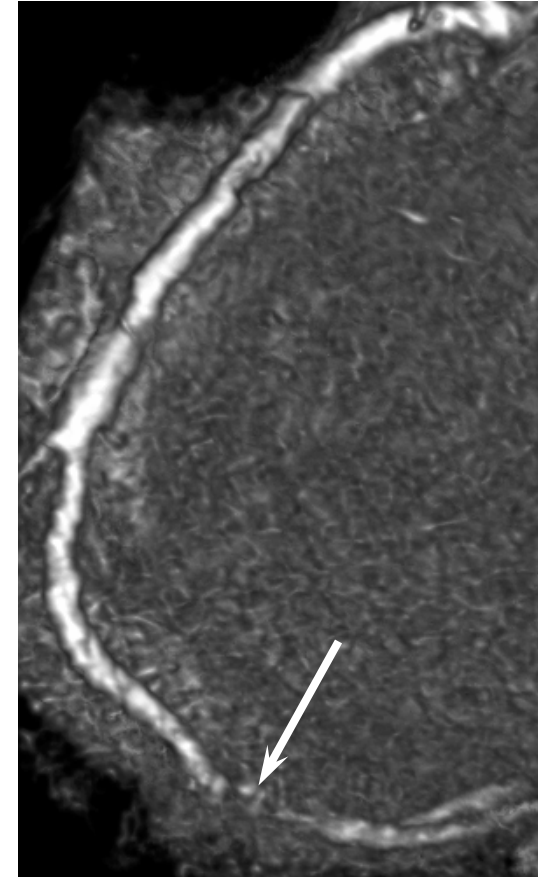
'04.9.28~ Angina at rest

**Coronary risk factor:**

DM, smoking

**MSCT findings: '04.10.13**

Severe stenosis at *distal RCA*







## CCT 2004 Live Case Demonstrations

*Toyohashi Heart Center*

CCT 2004

*Case 2-25 M. O. 81 y.o. male*

*Target Lesion: Mid RCA*

**Diagnosis: AP**

**Present illness:**

'02.3.~ EA

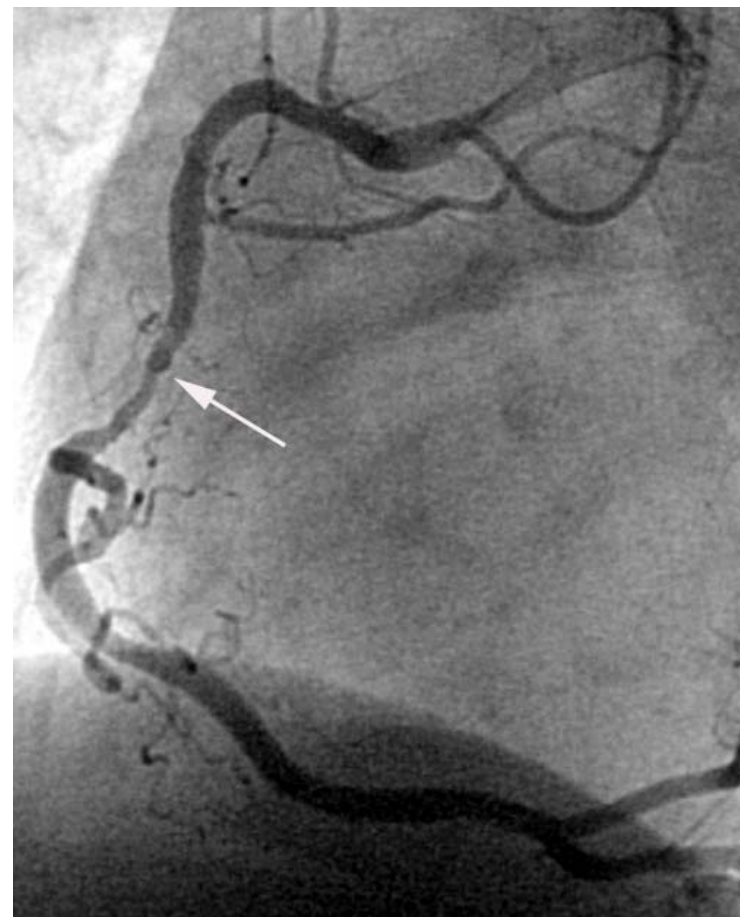**Coronary risk factor:**

HT, smoking

**Final CAG findings: '04.10.13**

**LVEF: 60%**

**CAG: *mid RCA 75%, mid LAD 50%,  
prox. LCx 50%, D1 75%***





CCT 2004

## CCT 2004 Live Case Demonstrations

*Toyohashi Heart Center*

***Case 2-26 M. I. 59 y.o. female***

***Target Lesion: Prox. RCA***

**Diagnosis: AP**

**Present illness:**

'03.3.26 DCA (*Prox. LAD & Ostial D1*)

'04.4.8 Stent (*Prox. RCA, DuraFlex*)

**Coronary risk factor:**

HT

**Final CAG findings: '04.10.16**

**LVEF: 65%**

**CAG: *prox. RCA 90%, mid RCA 50%***

***prox. LAD 50%, D1 50%***

