

## **Direct Stenting Without Pre-dilatation for Acute Myocardial Infarction**

Hoshi General Hospital, Koriyama

by Mikihiro Kijima

Acute myocardial infarction (AMI) is known to develop in many cases as a result of the rupture and collapse of comparatively soft unstable plaque. Judging from our own intravascular ultrasound (IVUS) evidence, though calcification is sometimes seen proximal to a culprit lesion, it rarely occurs in the middle of a lesion. If a stent can be passed across a lesion, it is assumed that dilation of the lesion site with the stent will be fairly easy even without balloon pre-dilatation. Whether the stent can be crossed to the lesion site depends on the degree of vessel constriction, lesion calcification or vessel tortuosity. The indications of specific lesions types are very important. Direct stenting is said to shorten procedural time and the time the patients spends under fluoroscopy, in addition to reducing the amount of contrast medium used, and minimizing overall medical costs. However, in the clinical setting of AMI, in which important information about the distal vasculature may not be available due to a completely occluded lesion, decision-making about the type, size and length of the stent to be used is complicated.

### **1. Indications for Direct Stenting**

Table 1 shows the indications for direct stenting. In principle, applications do not differ from those for conventional stenting. Some resistance when the stent passes the culprit lesion is to be expected because there

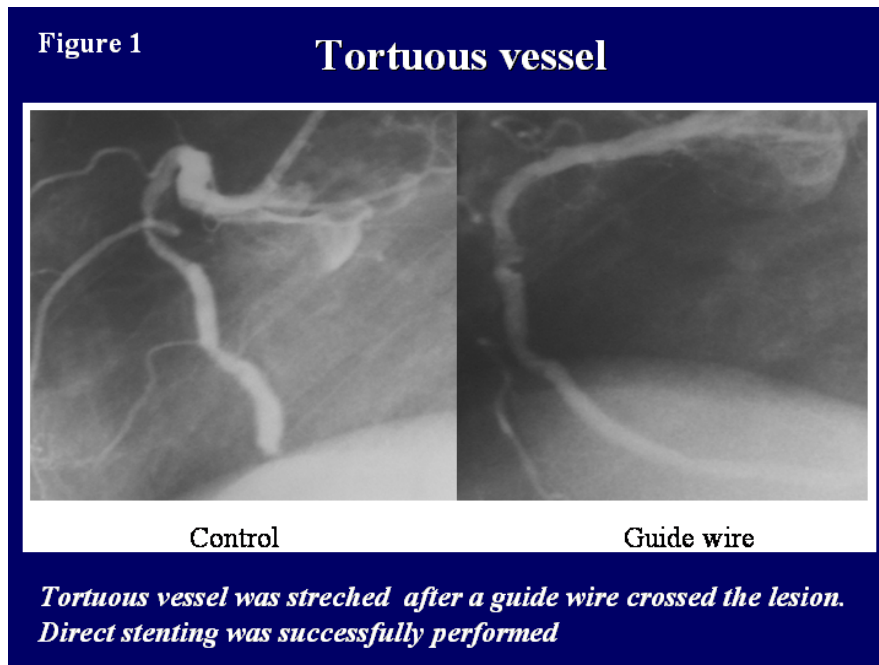
**Table.1**

### **Indication of direct stenting**

- (1) Within 24 hours from the onset**
- (2) Vessel diameter  $\geq 2.5$  mm**
- (3) No tortuosity or calcification proximal to the lesion**
- (4) No left main disease, No bypass graft disease**
- (5) Hemodynamically stable patients**

has been no pre-dilatation. This suggests that direct stenting is most suitable as a primary strategy for lesions in vessels with comparatively simpler anatomical conditions proximal to the lesion. Vessels with extensive snaking or tortuosity proximal to the lesions are best pre-dilated in the conventional way. This will obviously be necessary if the vessel shape is not straightened by the passing of a guidewire. Often, you will find that even in vessels with a high degree of snaking or tortuosity where conditions look unfavorable at first glance,

if the vessel dilates or straightens by having a guidewire pass, direct stenting may be feasible (Figure 1). Under coronary angiography, multi-branch calcification will often be detected in AMI patients, but this kind of disease is not necessarily suitable for direct stenting.



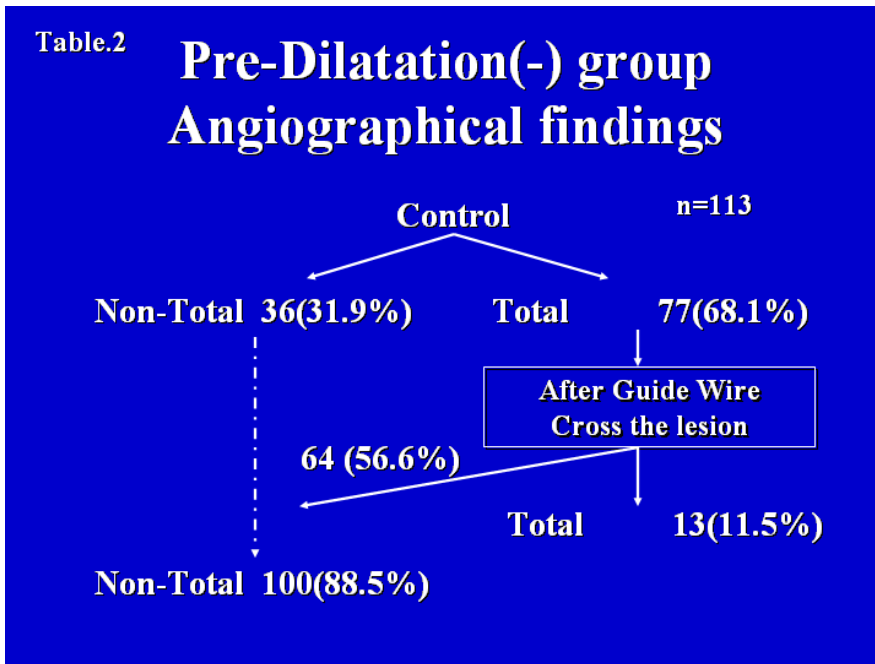
## 2. Guiding Catheter Selection

With direct stenting, as has been mentioned above, you tend to feel resistance when crossing the culprit lesion because you have not pre-dilated; crossing can be and very difficult. Back-up support providing by a guide catheter can compensate for this problem. Care should be taken to select a guiding catheter which enters the coronary artery as co-axially as possible and remains in close alignment with it. More specifically, use an Amplatz in cases where the RCA originates from the front of the aorta, or has a high angled arch, and when the LCA originates from the back upper part of the aorta. There will always be some cases where insertion of the guide catheters is complicated. When you find you cannot advance your guide catheter into the coronary vasculature at all, bring the guide catheter back to the aorta-ostium. Insert the guide catheter utilizing support from a guidewire, after crossing the guidewire distally into the artery you are trying to enter.

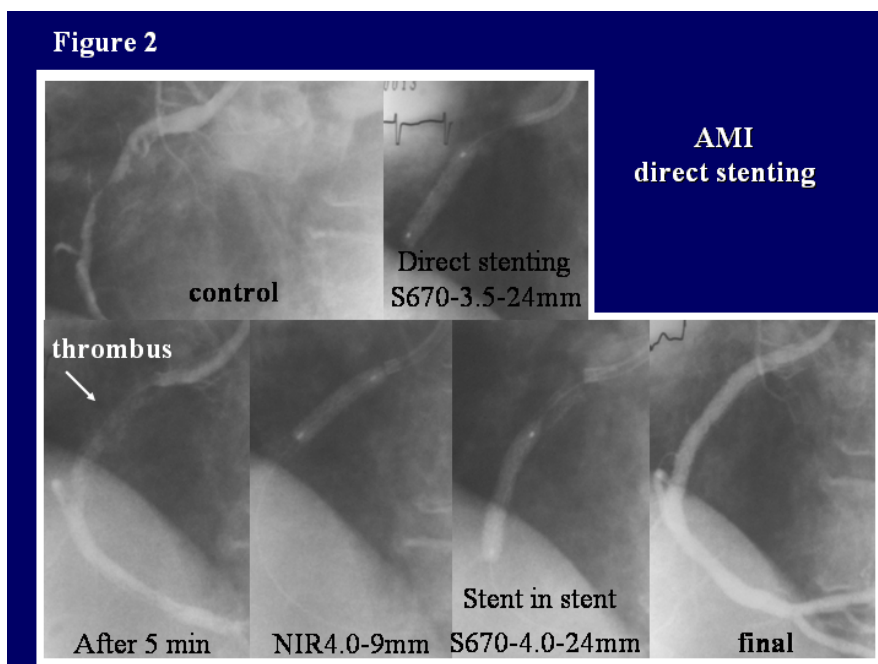
### 3. Stent Selection

When performing direct stenting for AMI, stent selection can be problematic. Decision-making will be particularly difficult, in AMI, if you have little or no information about the distal vessel, such as in the case of a complete occlusion. Our results from a multi-center study, however, suggest that in over 85% of cases, some kind of information about the distal vessel was available once the guidewire had crossed, including cases of natural re-canalization (Table 2). Stent selection should be done after the guidewire has crossed the lesion. In principle, we opt for tubular stents. The reason is that there is less plaque shift with tubular stents than with coil-stents, and there is also

the reduced risk of distal embolization due to the greater pressure exerted on any thrombus and unstable plaque at the vessel wall. Since it is common to find thrombus proximal to the lesion, we tend to select stents slightly longer than the actual lesion. Figure 2 shows a 3.5× 18mm S670 coil stent which was inserted into a completely occluded RCA in the setting of AMI. Due to a deterioration in blood-flow

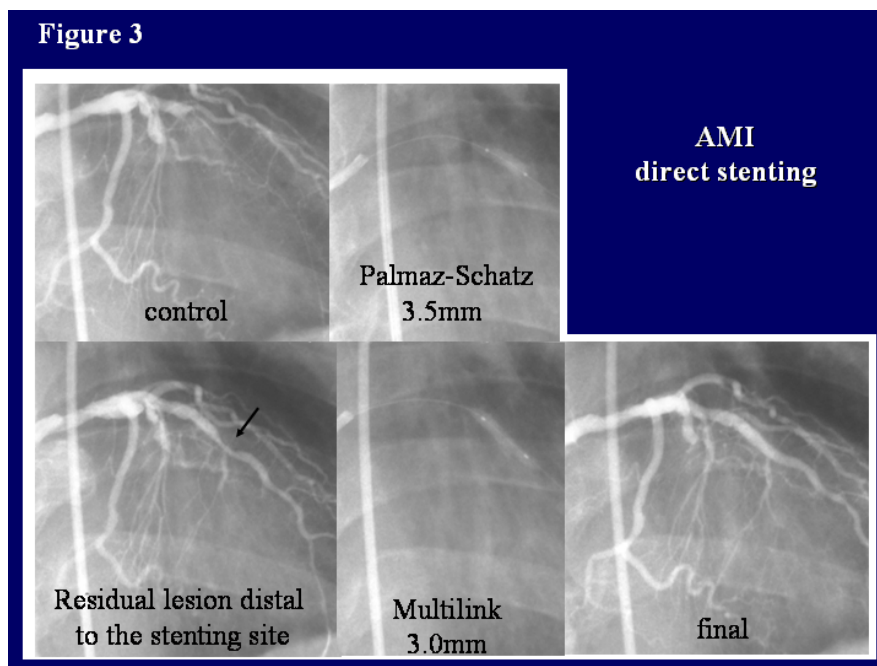


caused by embolization of thrombus or plaque debris, we implanted a 4.0× 24mm S670 stent from only across the lesion, from proximal to distal. We then followed up with a 4.0× 9 mm NIR stent to cover the area



proximal to the lesion, and an excellent result was obtained. However, tubular stents often have poor crossability and a coil stent may sometimes be selected if the vasculature is anatomically complex. Also, the presence of a large side-branch may mean that the most suitable stent to use is the highly-crossable ACS Multilink Stent.

If you cannot see the distal vessel under coronary angiography even after the guidewire has crossed, the lesion may not be indicated for direct stenting. Bear in mind though that rupture of plaques >15 mm is rare. Dilate the lesion using a stent around 15 mm and taking as your reference diameter the vessel proximal to the lesion. If you suspect there is more stenosis distally, confirm that by angiography and implant a second stent, if necessary. As distal vessel diameter is unknown, dilate at a low pressure of about 6atm the first time, and then at 12~16atm. Make sure the balloon tip is entirely inside the stent by pulling back slightly. Reassess the site again with angiography, and from the information you obtain about the distal vessel, decide whether to redilate the distal portion of the stent at high pressure or to implant a second stent. Figure 3 demonstrated a case of this kind. In a completely-occluded LAD mid-portion, the vessel remained occluded after being crossed with a guidewire. Lesion length and distal vessel diameter are unknown. A 3.5× 15mm Palmaz-Schatz stent was implanted using the proximal vessel diameter as a reference, but when subsequent angiog-

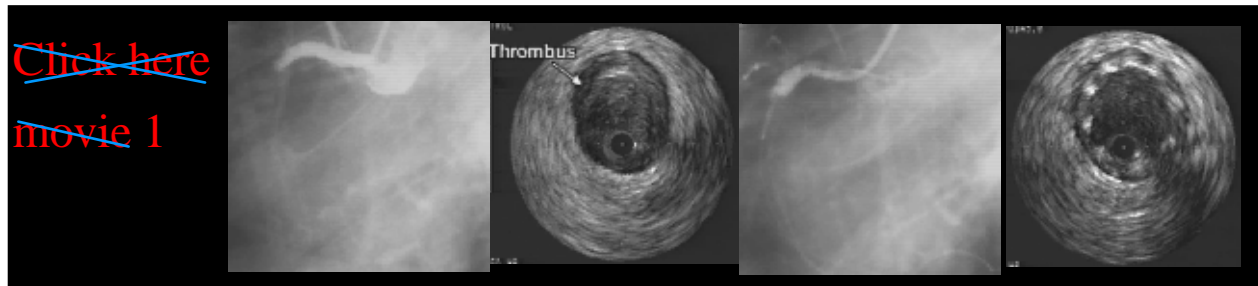


raphy showed that residual stenosis distal to the implanted stent, a second stent, a 3.0× 15mm Multilink was implanted with good results.

#### 4. Uses and Limitations of Direct Stenting

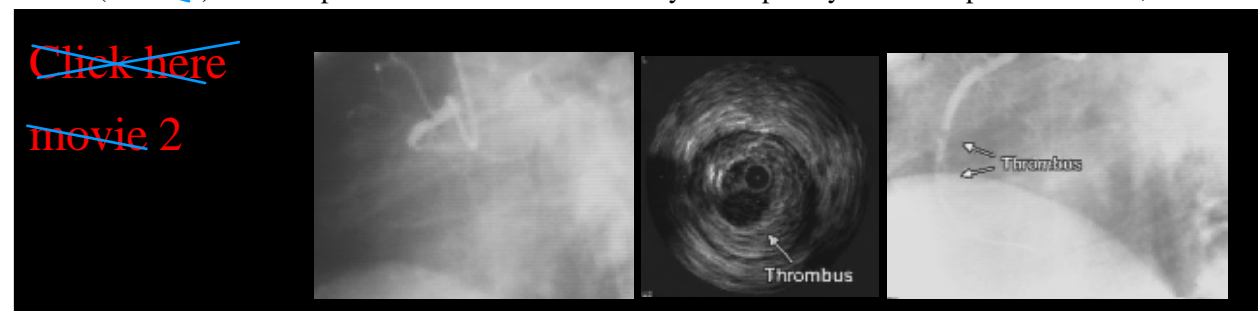
As mentioned above, the merits of directing stenting are reduced procedural and fluoroscopy times, reduced use of contrast medium and reduction in overall medical costs. Factors that directly affect the success or failure of the procedure are (1) the potential reduction in the risk of coronary arteries dissection caused by pre-dilation, and (2) the reduced risk of distal embolization from enhanced thrombus and plaque compression with direct stenting.

Case 1 (~~movie 1~~) shows a guidewire crossing a completely occluded proximal RCA in the setting of AMI,

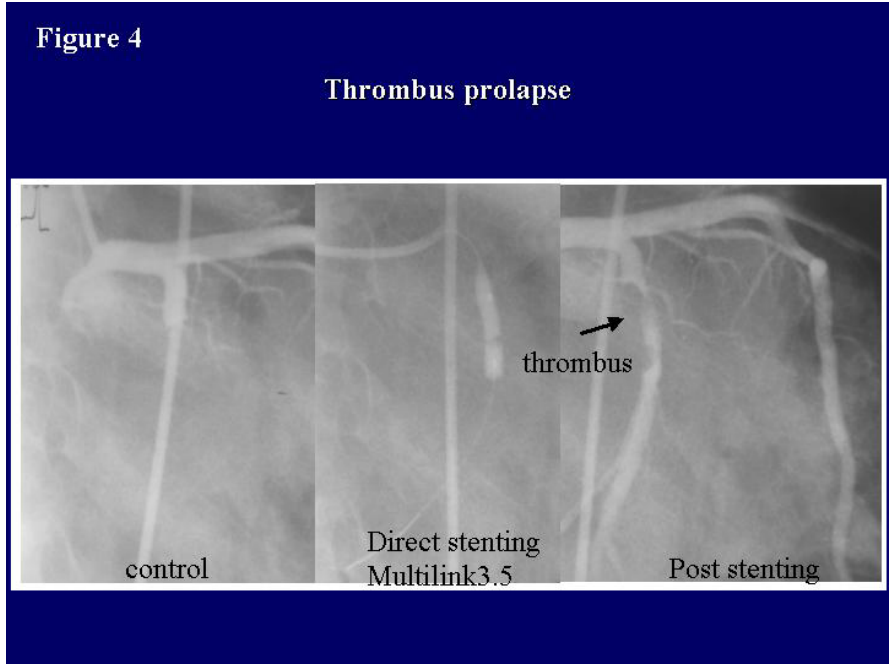


with thrombus detectable at the distal portion of the lesion site, further supported by the IVUS findings of a vulnerable-looking bulbous thrombus. Balloon pre-dilatation might easily cause distal embolization of the thrombus. We therefore opted for direct stenting, using a 4.0× 18mm NIR (a little longer than the length of the lesion), with a good final result.

Case 2 (~~movie 2~~) shows a patient with an AMI caused by a completely-occluded proximal RCA, in which

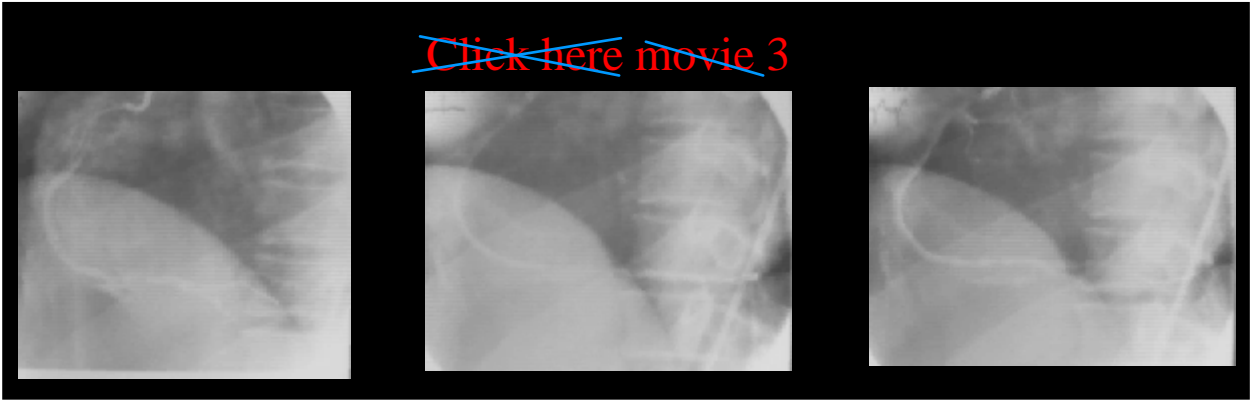


following the crossing of the guidewire, a large thrombus mass is observed from the proximal to distal portion of the lesion site. Similarly, IVUS also revealed a huge swollen thrombus. Given the concern about distal embolization, the decision was taken to perform direct stenting with a 3.5× 25mm NIR stent. Despite this, a large thrombus mass remained in the distal part of the lesion, with insufficient flow restoration. Ultimately, the patient suffered distal embolization in this artery. Figure 4 shows a similar case. Even after direct stenting



using a 3.5× 15mm Multilink, the embolization of a large number thrombus mass resulted in a poor final lumen and sub-optimal flow. Direct stenting has its limitations when there is a large mass of thrombus. Bail-out strategies must always be available in this kind of situation, such as a suction device or rescue catheter.

Case 3 (~~movie 3~~) shows a case of AMI with a completely occluded distal RCA distal. Thrombus is visible in



large quantities at the lesion, and the risk of distal embolism would seem to mean it is not indicated for direct stenting. So, we inserted a 6F guide catheter into an 8F guide catheter, and used suction to remove thrombus via the guide catheter from the lesion site. We then implanted a 3.5× 20mm Terumo stent and obtained a good result. This case suggest that that removing thrombus can be a useful way of ensuring adequate flow.

## 5. Results of A Multicenter Study

Tables 3 and 4 show the results of a multi-institutional study comparing patients treated with or without pre-dilatation, conducted in the manner already described above, with the decision to pre-dilate or perform direct stenting made on the same criteria as set out earlier. The success rate for stent implantation was >95%, which is high. Even cases where direct stenting was unsuccessful were successfully treated after crossing over to the pre-dilatation group. There were no significant differences in terms of the number of stents used in both groups. There were also no differences in major adverse clinical events, defined as death, sub-acute thrombosis, emergent bypass, no-reflow, acute coronary occlusion etc. Also, the frequency of distal embolization was significantly lower in the direct stenting group.

<b>Results</b>			
	<i>Pre (+)</i> <i>n=104</i>	<i>Pre (-)</i> <i>n=113</i>	<i>p value</i>
<i>Cross over</i>	<i>N/A</i>	<i>4/113 (3.5%)</i>	<i>n.s.</i>
<i>Delivery success</i>	<i>104/104 (100%)</i>	<i>109/113 (96.5%)</i>	<i>n.s.</i>
<i>Procedural success</i>	<i>104/104 (100%)</i>	<i>113/113 (100%)</i>	<i>n.s.</i>
<i>No. of balloons used per patient</i>	<i>1.16 ± 0.46</i>	<i>0.16 ± 0.41</i>	<i>p &lt; 0.0001</i>
<i>No. of stents used per patient</i>	<i>1.10 ± 0.36</i>	<i>1.17 ± 0.40</i>	<i>n.s.</i>

<b>complications</b>			
	<i>Pre (+)</i>	<i>Pre (-)</i>	<i>p value</i>
<i>Death</i>	<i>4</i>	<i>2</i>	<i>n.s.</i>
<i>SAT</i>	<i>3</i>	<i>3</i>	<i>n.s.</i>
<i>CABG</i>	<i>0</i>	<i>1</i>	<i>n.s.</i>
<i>No reflow</i>	<i>4</i>	<i>3</i>	<i>n.s.</i>
<i>Acute occlusion</i>	<i>1</i>	<i>0</i>	<i>n.s.</i>
<i>Any MACE</i>	<i>11 (10.6%)</i>	<i>7 (6.2%)</i>	<i>n.s. (0.33)</i>
<i>Distal embolism</i>	<i>16</i>	<i>7</i>	<i>0.028</i>

## **6. Overview of Direct Stenting**

The results of our multi-institutional study indicate that even though direct stenting for AMI is a less common strategy than conventional stenting, the results are the same or even better. Coronary angiography allows imaging of the vessel distal to the culprit lesion, and direct stenting may be an effective method in this setting when there is not an excessive thrombus burden. It is no exaggeration to say that coronary intervention for AMI is a battle against thrombus. In the presence of a large thrombus mass, treatment of the thrombus prior to stent-implantation is a key factor for overall success.

As stents with ever more excellent delivery systems are developed, the indications for direct stenting can be expected to expand even further. Not only in AMI but also for angina pectoris and other elective cases, direct stenting may be a useful strategy for cases where the soft plaque makes stent delivery relatively straightforward. Balloon pre-dilation can cause dissection which requires bail-out using not only longer but often multiple stents. However, the golden rule to bear in mind when your stent will not pass the lesion, is not to force it, but to pull out, and pre-dilate with a balloon, before going on to implant the stent.