

Lesion crossing by a guide wire is the first step in the successful intervention treatment of coronary heart diseases. Today, we have various kind of guide wires for coronary intervention and .014 flex wire is the first line among them to be used for every kind of lesion except for chronic total occlusion. To cross wire to chronic total occlusion and some stent struts, stiffer-tip wires are sometimes necessary. The wire selection, the shaping of wire tip curve and the method of wire manipulation including specific technique are basic considerations for successful wire crossing through individual lesion to be treated.

- a) Wire selection: Functions of the wire to be used for coronary interventions are divided into two major parts, namely lesion selection and lesion crossing or penetration. The performance of the guide wire is related to the stiffness of its tip and the torque control of the wire. To select a lesion effectively, soft wire tip and good torque control of the wire shaft are mandatory. To select or to cross the lesion, we need the optimal stiffness of wire tip and the optimal control of torque of the wire. Ideally one-to-one torque control is easiest to control the wire tip direction to select the stenosed lesions, side branches and especially irregular lesions. Various kinds of wire tip in stiffness are needed to cross various kinds of lesions in stiffness. There are many kinds of lesions in stiffness which operators attempt to dilate by coronary intervention. To select wires for crossing specific lesions, operators should have enough knowledge about the relationship between stiffness of wire tip and stiffness of the stenosed or occluded coronary lesions. Selection of a lesion by wire is easier in a soft tipped wire than a stiff tipped wire. The stiff wires are more favorable for crossing or penetrating the lesions than the soft tipped wires but unfavorable for selection of soft lesions without making dissection. For a soft lesion like an infarct-related coronary occlusion and for a lesion responsible for an unstable angina, a flexible wire with soft tip is the most effective in crossing the lesion without wire-related coronary dissections. And for a chronic total occlusive lesion, stiffer tipped wire, e.g. standard wire, is necessary to cross the stiffer lesions without making wire-related false lumen. And stiff wires, not standard wires, are necessary to make a re-entry from a wire-related false lumen to a distal true lumen to get a successful recanalization in some cases. For intermediately stiff lesions like a lesion responsible for a recent myocardial infarction, intermediately stiff wires are suitable to cross the lesion. Intermediate wires are also effective in selecting irregular lesion with calcification and side branch occlusions after stent implantation. Hydrophilic coated wires might offer better torque control in some lesions, especially in severely tortuous lesions, but control of wire tip direction becomes sometimes more difficult in many ordinal lesions. Tapered tip wires are favorable for an increase in penetrating power for some lesions but the chance of making wire-related false lumen becomes higher than non-tapered tip wires by using them (Table 1).
- b) Shaping of wire tip: Shaping of wire tip curve is very important to select and cross lesions by a wire. Each lesion

**Table 1**

***Guide wire function***

	<b>function of wires</b>
<b>Floppy tip</b>	<b>selection &gt;&gt; penetration</b>
<b>Intermediate</b>	<b>selection &gt; penetration</b>
<b>Stiff tip</b>	<b>selection &lt; penetration</b>
<b>Ultrastiff tip</b>	<b>selection &lt;&lt; penetration</b>
<b>Coated wire</b>	<b>better torque</b>
<b>Tapered tip</b>	<b>penetration</b>

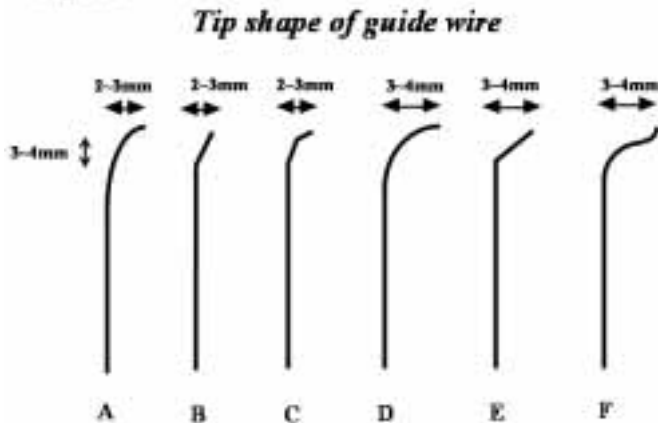
attempted has a specific anatomy, a specific vessel size and a specific tortuosity, which requires a specified curve of wire tip to be used effectively. To select left anterior descending artery(LAD) from left circumflex artery(LCX), we sometimes need big curves of the wire tip, and small curves of the wire tip are easier than big curves to select small artery. The length of wire tip bent should be equal to the diameter of the reference vessel and the degree of angle of the wire tip bent is depend on the angle of the attempted vessel. If the branch has an obtuse angle to the main artery, an obtuse angle of the wire tip is suitable to select the side branch, and if the main vessel has an acute angle to the side branch, 45°~90° of wire tip angle is helpful to select the lesion.

For example, an obtuse angle is suitable to select diagonal branches from LAD and an acute angle is easier to select septal branches from LAD. Some times the operator needs two types of wire tip curve for one lesion. Big curve of wire tip is necessary to cross the first anatomy proximal to the lesion and small curve for the lesion. Using over the wire system has an advantage in this case because of easy change of wire curves after crossing the proximal anatomy. The recommended angle of wire tip bent is similar in case of stiff wires for stiff lesions, e.g. chronic total

occlusions (Fig.1).

c) Wire manipulation: Recent advancement of wire technology gave operators many kinds of guide wires with good performance so that operator might handle guide wire by single hand to select some lesions, however wire manipulation by single hand in complex lesion is usually difficult to get successful crossing. Basically in coronary intervention, wire should be manipulated by both hands. The role of the left hand is to push/pull the wire tip in short length (1~5mm) and the role of the right hand is to control wire tip direction toward attempted coronary vessel, e.g. LAD or LCX. To get cross complex lesions in many cases, we need fine wire manipulation. Sometimes we need to advance wire tip 1mm or 2 mm in length to get the correct target vessel while we keep the wire tip direction toward the target vessel. In some instance, advancement of wire tip and change of the direction of wire tip are done simultaneously to select the target lesion. Wire manipulation by both hands is easier than single hand manipulation in many complex lesions, especially in chronic total occlusions (Fig.2).

Figure 1.



Wire manipulation by both hands is easier than single hand manipulation in many complex lesions, especially in chronic total occlusions (Fig.2).

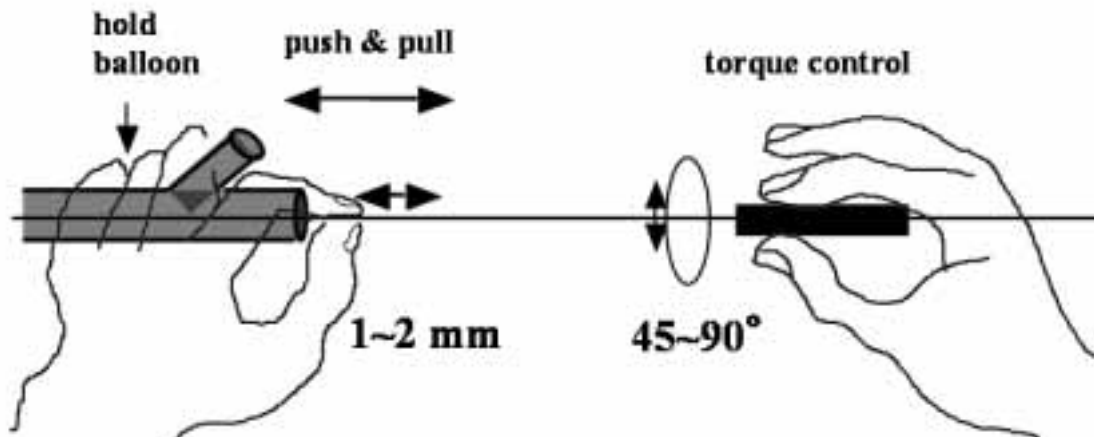
d) Special wire technique:

1) Deep angle at bifurcation: Basically wire tip curve should be considered according to the anatomy at bifurcation. To select side branch which originates acutely from main vessel, special curve

of wire tip is sometimes necessary. For example, selection of LCX with acute angle to LAD and selection of diagonal branch with acute angle to LAD are difficult by usual curve of wire tip. Big curve with steep angle of the

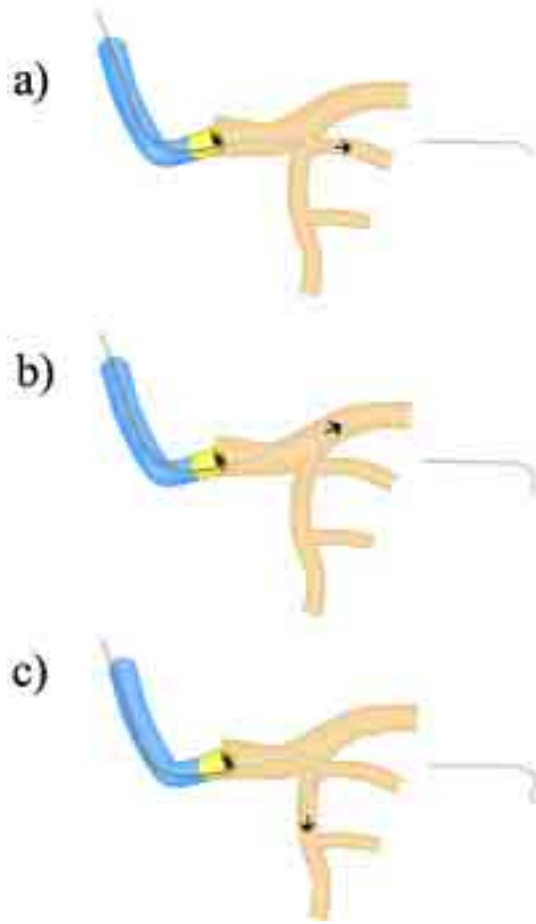
Figure 2.

### How to operate a guidewire



wire tip is mandatory for this kind of anatomy (fig. 3a). If the coronary main vessel size is small, small curve with acute angle of wire tip is recommendable. And sometimes Amplatz type wire tip curve is helpful to select side branches in this situation (fig. 3c). In this condition, wire prolapse frequently occurs when push flexible wire to advance deeply (Fig. 3b). Change of the wire from flexible to intermediate may solve prolapse problem in some cases, although the risk of creating false lumen related to stiff wire increases. Over the wire balloon system is easier to change the curve of wire tip frequently than monorail system. Fine torque control of the wire tip during pulling or pushing wire is also important to use the wire tip functionally. After getting the orifice of attempted branch pushing the wire may cause wire prolapse from the orifice. To avoid prolapse, modest clockwise or counterclockwise rotation of the wire tip is helpful. The efficacious direction of rotation of the wire depends on individual anatomy at bifurcation. Fine wire manipulation by both hands (push or pull by the mm order by left fingers and control torque modestly by right fingers) is essential to cross wires into side branches with this kind of anatomy.

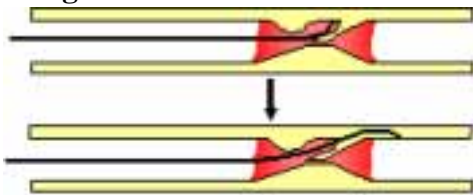
**Figure 3**



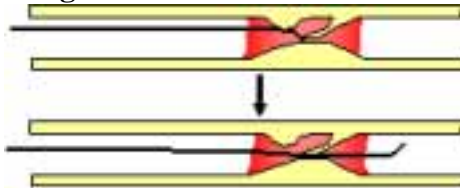
lesion without making wire related dissection in many cases. Wire manipulation by both hands is mandatory to select difficult anatomy (Fig. 7).

2) Infarct related lesion: In acute myocardial infarction (MI), the culprit lesion is usually containing thrombus but infarct related lesion is soft enough to allow soft wire to cross easily. However, there are some specific anatomical variations that may cause wire cross difficult. One is a presence of aneurysm formation attributed to plaque rupture and the other is severe tortuosity in the occluded segment. Plaque rupture causes thrombus formation leading to vessel occlusion and sometimes remains small aneurysm or intimal flap that protrudes in the remaining lumen. In the majority of acute MI cases, an operator is not able to get further anatomical information about the presence of aneurysm or intimal flap from the diagnostic angiogram. The only information for this kind of complex anatomy can be obtained from the presence of some resistance to the wire tip advanced into the occluded segment. When the wire tip goes into the aneurysm there may be some resistance at distal wall of the aneurysm (Fig. 4). Advancement of wire tip in this situation may cause new long dissection to the distal part of occlusion and lead to no reflow after balloon dilatation. In this case, an operator has to manipulate soft wire gently and be aware of the presence of such kind of anatomy before pushing the wire forcefully. And an operator should try to cross the lesion gently with a few different curves of the tip with soft wire before using stiffer wire to penetrate the lesion. Usually steeper angle of the wire tip allows easier selection of distal true lumen from aneurysm or subintimal space (Fig. 5). In case of the presence of acute angle in the occluded segment there is also some risks of wire related new dissection when push the wire forcefully against resistance (Fig. 6). Change of the curve of wire tip to steeper angle allows the wire tip to cross the

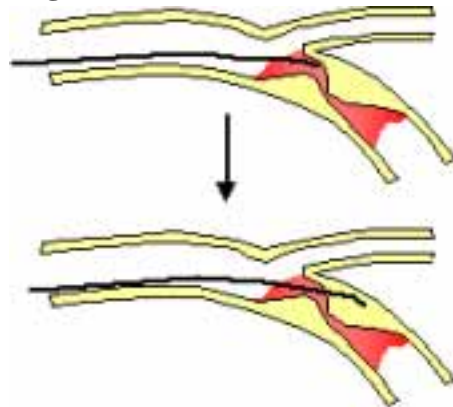
**Fig.4**



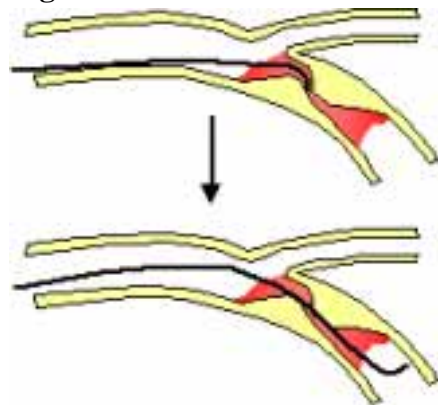
**Fig.5**



**Fig.6**

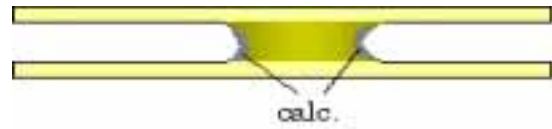


**Fig.7**



3) Chronic total occlusion: For the intervention to chronic total occlusion, there are special considerations about the selection of guide wire suitable for the individual lesion. The total occlusion has various kinds of anatomy in the occluded segments including duration of occlusion, eccentricity, length, tortuosity, fibrous tissue, calcification, presence of side branches and so on. It is impossible for an operator to know every information from the diagnostic cine angiogram before the procedure. Most remarkable difference in wire selection in CTO from the patent stenosed lesions is the stiffness of wire tip for the lesion attempted. The lesions with younger than 1-month occlusion have mildly stiff tissue in the occluded segment, and lesions with 3-month to 6-month occlusion have moderately stiff tissue and old total occlusions longer than 6-month occlusion have more hard mass including calcification in the segment. Basically soft wire is suitable to non-occluded lesions or acute MI related lesions; intermediate wire is effective to younger occlusions and stiff wire is necessary to cross old occlusions. Importance of optimal shaping of wire tip to select the occluded lesions is similar to that of non-occluded vessel intervention (Fig.1). Different wire function expected in CTO is penetrating function of the wire tip against hard mass or calcification in the lesion. Through the occluded segment, there are two main part where hard mass is present, one is

**Fig.8a**



**Fig.8b**



**Fig.8c**



**Fig.9a**



**Fig.9b**



**Fig.9c**

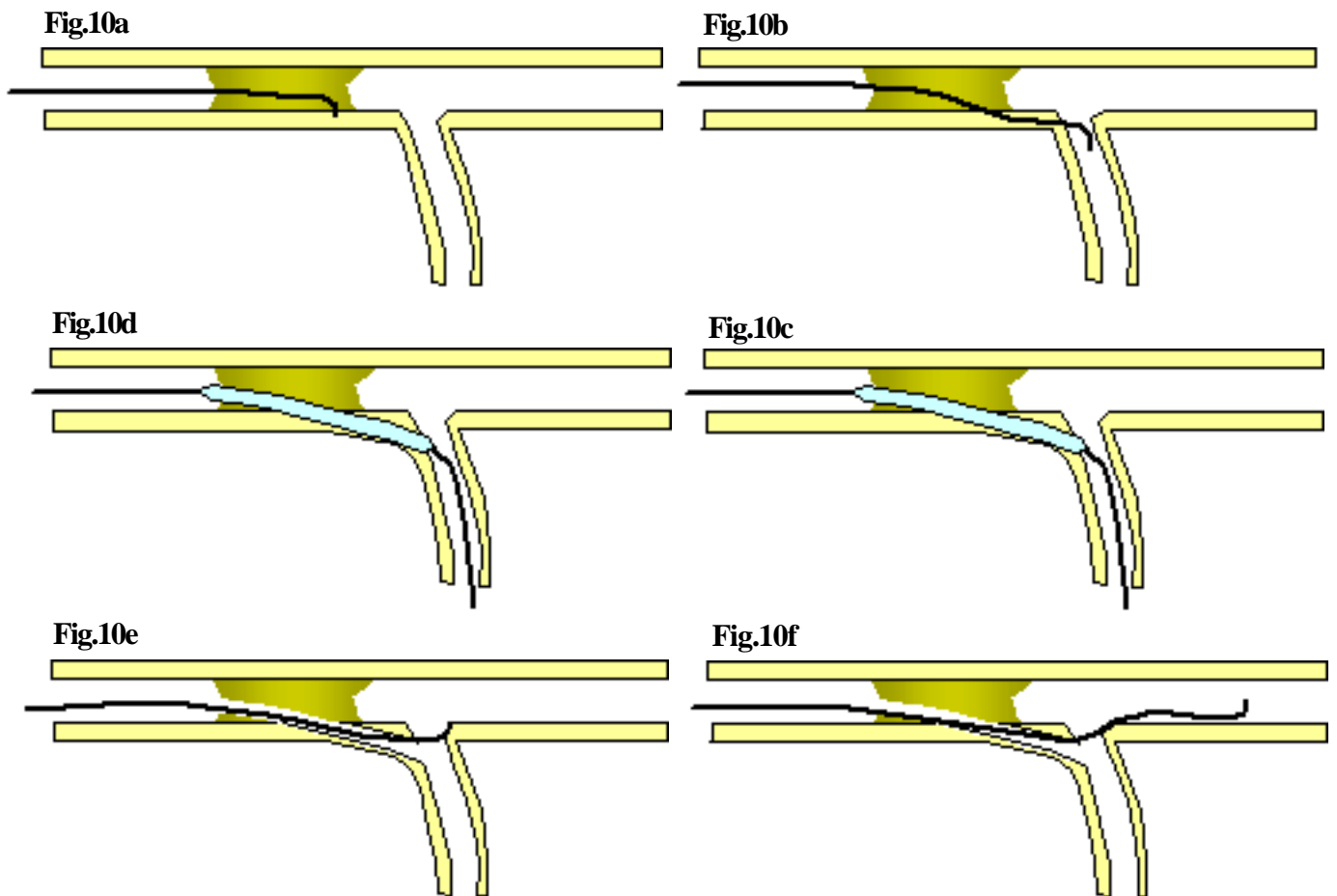


**Fig.9d**



the orifice of the occlusion and the other is the exit of the occlusion. The two parts frequently consist of calcification in old total occlusions by IVUS examination after dilatation. For these hard parts of occlusions we need stiff wire to penetrate the hard tissues, but between the two parts there is usually soft mass that need not stiff wire to cross. Another feature of CTO intervention is crossing wire to occluded target lesion through the non-occluded proximal segment. Use stiff wire from the orifice of the coronary artery is sometimes dangerous because stiff wire is likely to enter the subintimal space in healthy coronary vessel under the condition of tortuosity. Our routine of selection of wire is that use soft wire first for the proximal non-occluded segment and exchange to stiffer wire through over the wire system step by step according to the stiffness of occluded target segment. To cross the entry point of total occlusion we sometimes need stiff wire and to cross exit point more stiff wire is needed depending upon the stiffness of tissue including fibrous tissue or calcification. Stiff wire is used basically to penetrate hard tissue, so that frequent exchange to wires with different stiffness in tip and different tip curve of same wire is needed to get cross the lesion (Figure 8a, 8b, 8c). In the occluded segment wire manipulation is done according to the known distal anatomy imaged by contra-lateral dye injection. Usually crossing entry point is rather easy than crossing exit point because the entry point has concave anatomy in many cases while distal exit point has convex anatomy. After successful crossing of entry point wire is manipu-

lated intentionally toward the exit point imaged by collateral. To know where the wire tip is in the occluded segment movement of wire tip and exit point during beating cycle of the heart is only helpful information. In case the wire tip is placed in the occluded original lumen, the movement of wire tip is similar to the movement of exit point. If the wire tip penetrates the occluded vessel wall and is placed outside of the vessel wall, wire tip motion in the beating cycle is different pattern from the motion of the exit point (gap of the motion between wire tip and exit). After the wire tip comes close to the distal end of the occlusion, next job is penetrating distal hard tissue into the distal true lumen. To penetrate the distal hard tissue by wire, operator needs various wires in stiffness according to hardness of the distal end and sometimes use of back-up support by balloon to stiffen the wire tip is effective. Careful check of wire position by cine angiogram of two orthogonal views avoids careless failure caused by stiff wire related false lumen or perforation. The false lumen tends to compress distal true lumen and distal end becomes hard to see by contra-lateral angiogram. In this case waiting for 10 to 20 minutes allows recovery of the distal flow through the collateral flow. Another option to choose in this situation is use of the second stiff wire remaining the first wire in place and select the correct entry point again by the second wire (Figure 9a, 9b, 9c, 9d).



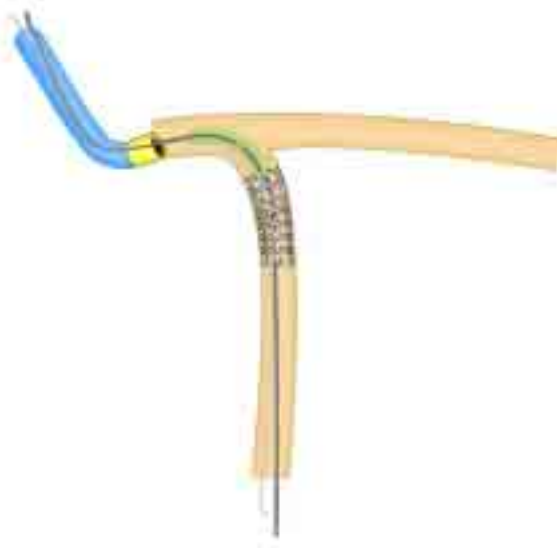
This two-wire method favors the operator saving dye consumption because of the presence of the first wire as a marker of vessel wall and avoiding extension of false lumen created by the first wire. The drawback of the two-wire method is difficulty in manipulation of the second wire because of the presence of the first wire in the narrow occluded space. After crossing the wire through occluded segment to distal true lumen operator can get free movement of the wire tip in the correct position. But in some cases resistance against wire movement remains after successful crossing because of tight lesion in the occluded segment. In this case selection of distal small branches by same wire offers warrant for successful wire crossing. The wire tip placed in the small branch moves similarly to the original motion of small branches and finally wire stimulated ventricular premature beats suggests that wire tip is placed in the end of the branch. Another technique to cross wire to true distal lumen after failure of intended penetration of the wire at the exit point is side branch technique. Intentional penetration to small side branch distal to the exit from false lumen using stiff wire is relatively easy with an increased risk of wire perforation. Balloon dilatation to the side branch using small size balloon makes connecting channel through false lumen to distal true lumen in some cases. After creating connecting channel, operator may select distal true lumen by fine manipulation of wire (Fig. 10a, 10b, 10c, 10d, 10e, 10f).

- 4) Double wire: Use of multiple wires is sometimes effective to achieve successful intervention results. To treat bifurcation lesion protection of side branch occlusion by the second wire is essential in case with wide territory covered by the side branch. We attempt wiring to the vessel with difficult anatomy first and secondary to the vessel with easier anatomy for wiring. The drawback of two wire technique for the purpose of side branch protection is twist of the two wires that makes balloon advancement difficult. In this case re-wiring of the second

wire is the easiest solution of the problem. The buddy wire is used in case with difficult anatomy for stent implantation. There is no technical difficulty about wiring of the second wire except for twist of the two wires as a result. Powerful pushing of stent delivery system may solve the twist of two wires. Another solution of this problem is re-wiring of the first wire from the first twisting point of two wires. If the balloon or stent delivery balloon stuck at the twisting point, operator needs to pull back the wire to balloon tip and to select distal vessel again, which is the best way to avoid repeated twist of wires at proximal portion to target lesion. Another application of two-wire technique is wiring for chronic total occlusion. After failure of the first stiff wire to cross occluded lesion, use of the second stiff wire is sometimes effective to cross the lesion successfully. Operator can use the first wire as a marker wire placed in false lumen. The drawback of this method is difficulty of wire manipulation. The second wire tip must be stiffer than the first wire to select distal true lumen.

- 5) Stent strut: Although basic consideration of wire manipulation in stenting is as same as balloon angioplasty, there are some specific wire manipulation techniques regarding to stenting. On stent implantation, severe tortuosity, diffusely diseased lesion, calcification and stent proximal to the target lesion are obstacles to new stent implantation. In case of severe tortuosity, exchange of the guide wire to support wire may favor the stent delivery system crossing to target lesion. And use of two support wires to straighten the proximal tortuosity may improve the crossability of the stent delivery system. Calcification proximal to the lesion acts as resistance to crossing the stent delivery system because of the fixed irregular surface of the inner vessel wall. Parallel two or three wire technique is sometimes helpful in this setting. Post dilatation balloon sometimes sticks in the proximal stent edge after stent implantation. In this case use of one more wire to advance the balloon may solve the problem. The shaft of the second wire may be placed other site of the stent edge by chance and post dilatation balloon may be advanced without contact with stent edge (Fig. 11). Another easier solution of this problem is use of soft part of the same wire by pulling back the wire to the stent. Because the flexible part of the wire is free in the stent, stuck balloon tip may become free from stent strut (Fig. 12).

**Figure 11**



**Figure 12**

